

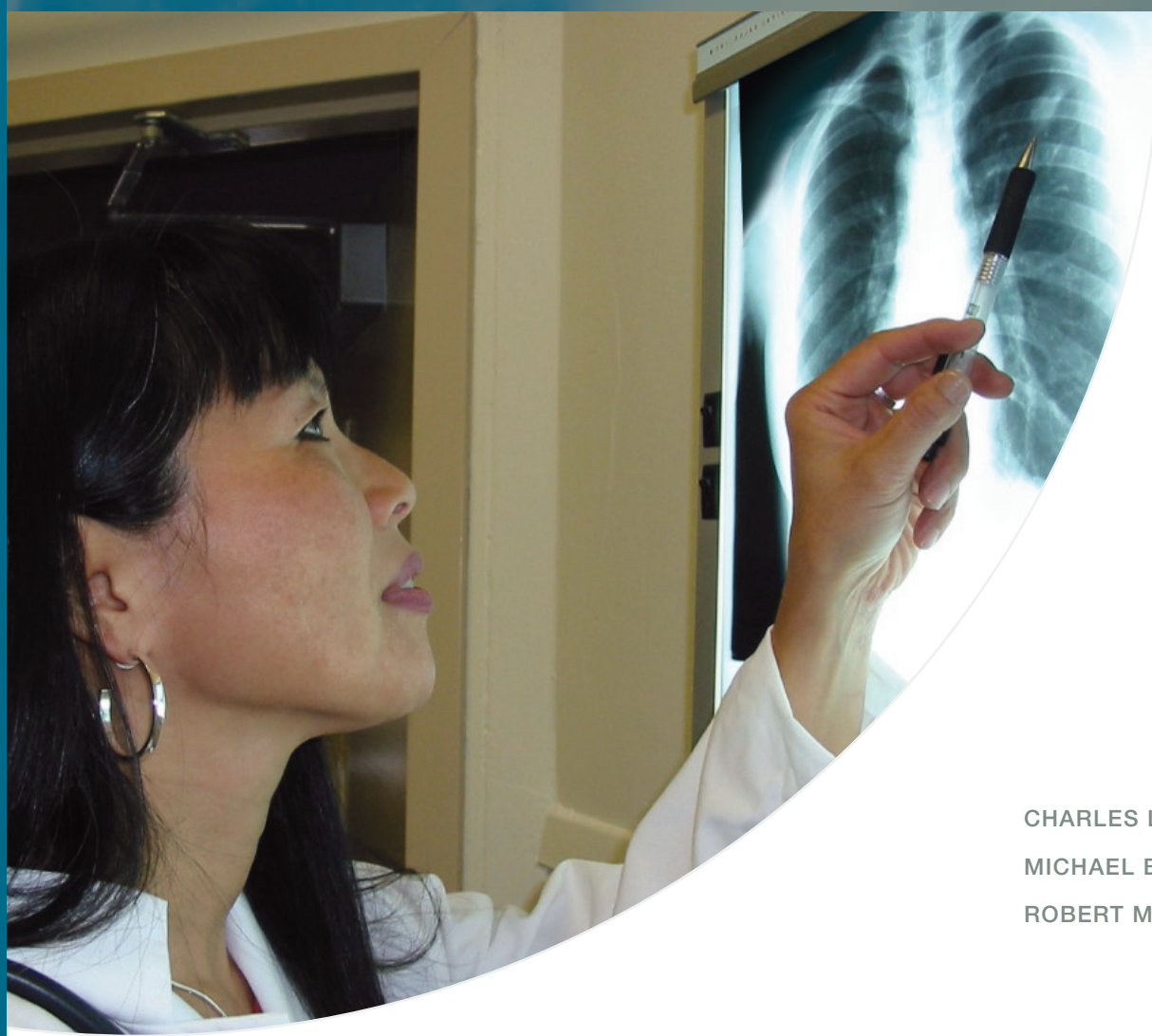CURRY  
INTERNATIONAL  
TUBERCULOSIS  
CENTER

A PRIMER FOR CLINICIANS

# Radiographic Manifestations of Tuberculosis

SECOND EDITION, 2011



CHARLES L. DALEY, MD  
MICHAEL B. GOTWAY, MD  
ROBERT M. JASMER, MD



CURRY  
INTERNATIONAL  
TUBERCULOSIS  
CENTER

A PRIMER FOR CLINICIANS

# Radiographic Manifestations of Tuberculosis

SECOND EDITION, 2011

CHARLES L. DALEY, MD  
MICHAEL B. GOTWAY, MD  
ROBERT M. JASMER, MD



This project was funded through the Department of Public Health, City and County of San Francisco, with funds awarded under Cooperative Agreement U52/CCU900454, Centers for Disease Control and Prevention.

Funds were also provided through the National Heart, Lung and Blood Institute, Tuberculosis Academic Award Program, KO7-HL03057 at the University of California, San Francisco.

Permission is granted for nonprofit educational uses and library duplication and distribution.

Suggested citation:

Daley CL, Gotway MB, Jasmer RM.  
*Radiographic Manifestations of Tuberculosis: A Primer for Clinicians, Second Edition*  
San Francisco: Curry International Tuberculosis Center;  
January 2011: [inclusive page numbers]. Termination date: January 2014

The faculty for this publication, Drs. Charles L. Daley, Michael B. Gotway, and Robert M. Jasmer, have indicated that they have not had any financial arrangements or affiliations with commercial sponsors that have direct interest in the subject matter.

## ***About the Authors***

**Charles L. Daley, MD**, is a Professor of Medicine at the National Jewish Medical and Research Center and the University of Colorado Health Sciences Center. He is Head of the Division of Mycobacterial and Respiratory Infections at National Jewish Medical and Research Center.

**Michael B. Gotway, MD**, is a Radiologist with Scottsdale Medical Imaging, an affiliate of Southwest Diagnostic Imaging. He is also Clinical Associate Professor of Radiology and Medicine at the University of California, San Francisco. He is the former Acting Chief of Radiology and Director of Thoracic Imaging at the San Francisco General Hospital as well as the former Director of the Radiology Residency Training Program at the University of California, San Francisco.

**Robert M. Jasmer, MD**, is an Associate Clinical Professor of Medicine at the University of California, San Francisco. He is also an Attending Physician at the San Francisco Tuberculosis Clinic.

## ***Table of Contents***

<b>Acknowledgements</b>	<b>vii</b>
<b>Learning Objectives</b>	<b>viii</b>
<b>Foreword</b>	<b>ix</b>
<b>CHAPTER ONE: Basic Chest Radiograph Interpretation</b>	<b>1-10</b>
<b>Introduction</b>	<b>1-1</b>
<b>Basic Physics of the Radiographic Image</b>	<b>1-11</b>
X-ray Absorption	1-11
Factors Contributing to X-ray Absorption	1-11
Energy	1-11
Tissue Density	1-11
Differential X-ray Absorption: Why We See What We See	1-12
Normal Contours Created by Aerated Lung	1-12
<b>Basic Chest Radiographic Patterns: Normal Anatomy</b>	<b>1-14</b>
Frontal Chest Radiograph	1-14
Lateral Chest Radiograph	1-18
Interfaces	1-21
The Silhouette Sign	1-21
Assessing the Technical Quality of Radiographic Studies	1-23
Exposure, Positioning, and Inspiratory Effort	1-23
<b>Chest Radiograph Interpretation: Basic Patterns of Disease</b>	<b>1-24</b>
Consolidation (Airspace Opacity)	1-25
Air Bronchograms	1-25
Acinar Shadow	1-25
Interstitial Opacity:	1-27
Linear and Reticulation Opacity, Nodules, Miliary Pattern	1-27
and Peribronchovascular Thickening	1-27
<b>Self-Check One</b>	<b>1-33</b>
<b>Chest Radiograph Interpretation: Other Radiographic Patterns of Disease</b>	<b>1-35</b>
Nodules and Masses, Lymphadenopathy, Cysts and Cavities	
Pleural Disease	1-43
Pleural Effusion, Pleural Thickening, Calcification	1-43
Cardiomediastinal Contour Abnormalities and Soft Tissue	
and Osseous Abnormalities	1-45

<b>Self-Check Two</b>	<b>1-45</b>
<b>A Final Word about Evaluating the Entire Radiograph</b>	<b>1-49</b>
Distribution of Disease	1-50
<b>Conclusion</b>	<b>1-51</b>
<b>Self-Check Answers</b>	<b>1-52</b>
<b>References</b>	<b>1-52</b>
<b>CHAPTER TWO: Radiographic Manifestations of Tuberculosis</b>	<b>2-1</b>
<b>Introduction</b>	<b>2-1</b>
<b>Overview of the Pathogenesis of Tuberculosis</b>	<b>2-2</b>
<b>Primary Tuberculosis</b>	<b>2-3</b>
Distribution of Parenchymal Disease	2-3
Primary Tuberculosis in a Child	2-4
Primary Tuberculosis in an Adult	2-6
Patterns of Disease	2-7
Airspace Consolidation	2-7
Airspace Consolidation with Cavitation	2-9
Interstitial Pattern (Miliary)	2-10
Tracheobronchial Disease	2-11
Hilar and Mediastinal Lymphadenopathy	2-12
Pleural Disease	2-15
<b>Post-primary (Reactivation) Tuberculosis</b>	<b>2-17</b>
Distribution of Parenchymal Disease	2-18
Patterns of Disease	2-20
Airspace Consolidation	2-20
Airspace Consolidation with Cavitation	2-21
Airspace Consolidation with Bronchogenic Spread	2-22
Airspace Consolidation with Volume Loss	2-23
Interstitial Opacities (Miliary)	2-25
Tuberculoma	2-26
Pleural Disease	2-27
<b>Tuberculosis and HIV Infection</b>	<b>2-28</b>
<b>Resolution of Radiographic Abnormalities and Healed Tuberculosis</b>	<b>2-31</b>
Primary Tuberculosis	2-31
Post-primary Tuberculosis	2-31



<b><i>Self-Check Three</i></b>	<b>2-36</b>
<b>Conclusion</b>	<b>2-40</b>
<b>Self-Check Three Answers</b>	<b>2-41</b>
<b>References</b>	<b>2-44</b>
<b>CHAPTER THREE: Clinical Cases</b>	<b>3-1</b>
<b>Introduction</b>	<b>3-1</b>
<b>Case One</b>	<b>3-3</b>
<b>Case Two</b>	<b>3-5</b>
<b>Case Three</b>	<b>3-9</b>
<b>Case Four</b>	<b>3-11</b>
<b>Case Five</b>	<b>3-13</b>
<b>Case Six</b>	<b>3-15</b>
<b>Case Seven</b>	<b>3-19</b>
<b>Case Eight</b>	<b>3-21</b>
<b>Conclusion</b>	<b>3-23</b>
<b>References</b>	<b>3-24</b>
<b>Glossary</b>	<b>4-1</b>

## ***Acknowledgements***

Constructive reviews were kindly provided by:

Wafaa El-Sadr, MD, MPH  
Philip Hopewell, MD  
Michael Iademarco, MD, MPH  
L. Masae Kawamura, MD  
Venkatarama Koppaka, MD, PhD  
Ann M. Loeffler, MD  
Reynard McDonald, MD  
Kathleen Moser, MD, MPH  
Horacio Ramírez Oropeza, MD  
Randall Reves, MD  
Gisela Schecter, MD

This text was greatly helped by the technical assistance of David Berger, Catherine Minh Cao, and Jerry Libatique of the Curry International Tuberculosis Center in San Francisco; and Stella Park and Paula Doubleday.

A special thanks to Edi Berton for her cover design.

Finally, we would like to dedicate this book to our greatest inspiration, our patients at the San Francisco Tuberculosis Clinic and San Francisco General Hospital. They are the source of all of the radiographic images shown and continue to enrich us in our practice of medicine.

## ***Learning Objective***

**Upon completion of this course, participants will be able to:**

- A.** identify a tuberculosis suspect on the basis of a chest radiograph
- B.** describe appropriate management options based on the appearance of a chest radiograph

### **CHAPTER 1 – BASIC CHEST RADIOGRAPH INTERPRETATION**

**Objective 1:** Learners will be able to describe why normal anatomy and pathology may or may not be visualized using radiographs.

**Objective 2:** Learners will be able to gather information from the radiograph instead of using pattern recognition.

### **CHAPTER 2 – RADIOGRAPHIC MANIFESTATIONS OF TUBERCULOSIS**

**Objective 1:** Learners will be able to describe the radiographic manifestation of pulmonary tuberculosis and use standard terminology to describe the radiographic findings.

**Objective 2:** Learners will be able to recognize various radiographic manifestations of tuberculosis.

### **CHAPTER 3 – CLINICAL CASES**

**Objective 1:** Learners will apply knowledge to interpret clinical cases.

**Objective 2:** Learners will use case studies to describe the radiographic abnormalities and will answer questions relevant to the evaluation and treatment of the case.

## Foreword

**T**uberculosis conjures up many different images for both clinicians and laypersons, from the White Plague of centuries past to the sanatoria of the 19th century to impoverished people spreading resistant bacteria in urban areas in the 20th and 21st centuries. Despite many advances in both diagnosis and treatment, tuberculosis remains one of the most common causes of death from any infectious agent in the world. Currently, there are approximately 9 million cases of tuberculosis every year in the world, and it is hyperendemic in many countries of Africa, Southeast Asia, Latin America, and Eastern Europe. Roughly one-third of the world's population (2 billion people) is infected with *Mycobacterium tuberculosis*.

One of the most important and fascinating aspects of tuberculosis is the multiple forms it can take in radiographs of the chest. These differing radiographic appearances are often misunderstood and can easily be confused with other disease processes. In this text, we have set out to catalog the multiple chest radiographic manifestations of tuberculosis. Our intention is to make this as interactive an experience as possible, and we have included cases requiring readers' input as well as an entire chapter dedicated to case presentations with multiple choice questions.

Readers will note that, in several instances, portions of radiographs have been cropped to varying degrees. Of course, it is of paramount importance to adequately evaluate the quality of a radiograph prior to interpretation, and one step in this process is making certain that a portion of the radiograph has not been excluded from view. For the purposes of this text, cropping of the radiographs has been done to enhance the visualization of anatomy or pathology by increasing the resolution of the area of interest on the radiograph, and is a necessary step in providing high-quality radiographic reproductions.

The text has been divided into three chapters. The first consists of a basic discussion of what x-rays are, how images are created, and the skills necessary to read and interpret chest radiographs for the presence of disease. In the second chapter we provide examples of tuberculosis in all its multiple appearances. Finally, in the third chapter we present a series of cases to illustrate how the radiographic findings influence the evaluation and management of patients at risk for tuberculosis.



**CHAPTER ONE**

# ***Basic Chest Radiograph Interpretation***

## ***Introduction***

In Chapter One, we discuss the physical principles of plain chest radiography. By the end of this chapter, you should have a basic understanding of how chest radiographs are created and why normal anatomy and pathology may or may not be visualized using radiographs.

Armed with this knowledge, you will be able to gather information from the radiograph instead of simply offering a diagnosis because a particular radiograph superficially resembles a pattern you have seen before.

You will acquire skills to consistently and accurately read and interpret chest radiographs for the presence of disease using standard terminology. The proper use of standard terminology ensures that other clinicians are able to comprehend your interpretation and corroborate your diagnosis.

Once a framework of the principles of radiographic imaging is established, we discuss common chest radiographic patterns and differential diagnoses.

## ***Basic Physics of the Radiographic Image***

A discussion of x-ray photon interactions with matter is far beyond the scope of this chapter. However, we will explain general concepts underlying the creation of radiographic images. These include x-ray absorption, tissue density, and differential x-ray absorption.

### ***X-ray Absorption***

---

When x-rays are produced and directed toward the patient, they may act in three basic ways.

<b><i>They may be...</i></b>	<b><i>Which means...</i></b>
unabsorbed	they pass through the patient unchanged and strike the x-ray film.
completely absorbed	the energy of the x-ray is totally deposited within the patient.
scattered	they are deflected within the patient but may still strike the x-ray film.

### ***Factors Contributing to X-ray Absorption***

---

It is important to understand what factors contribute to x-ray absorption because the final image depends on the relative number of x-rays that are unabsorbed, absorbed, or scattered. In general, the two most important factors that determine how x-rays are absorbed are:

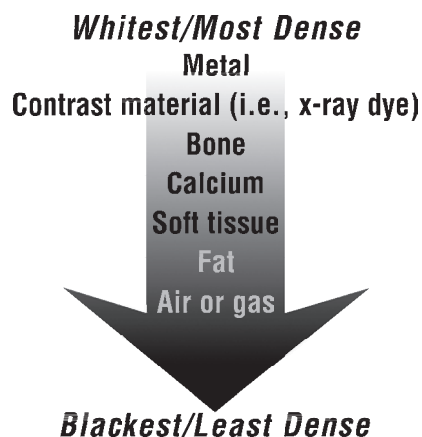
- the energy of the x-ray beam and
- the density of the tissue the beam strikes.

#### **Energy**

Because the energy of the beam is usually fairly constant in posteroanterior and lateral radiography, it is not an issue that needs further discussion.

#### **Tissue Density**



Of greater interest is the significant effect of tissue density on x-ray beam absorption. In general, you will see seven different densities on plain radiographs. The denser the tissue is, the whiter it appears on a radiograph. The less dense the tissue is, the blacker it appears. In order, from the densest (whitest) to least dense (blackest), the seven densities visible with chest radiography are:



All normal anatomic structures as well as the diverse range of cardiopulmonary abnormalities are visualized by the interplay among these seven densities. We explain how this is accomplished in the following section.

## ***Differential X-ray Absorption: Why We See What We See***

Depending on the tissue density, differing quantities of x-rays will be absorbed when the x-ray beam strikes the patient. This concept, called **differential x-ray absorption**, is the fundamental principle underlying plain radiographic image production and interpretation. In most cases, the higher the density, the greater the absorption of the x-ray photons.

<b><i>X-ray Photon Absorption</i></b>	<b><i>Substance</i></b>	<b><i>Radiographic Appearance</i></b>
<p><b>Highest</b></p>  <p><b>Lowest</b></p>	<ul style="list-style-type: none"> <li>• <b>Metal</b></li> <li>• <b>Contrast material (i.e., x-ray dye)</b></li> <li>• <b>Bone</b></li> <li>• <b>Calcium</b></li> <li>• <b>Soft tissue</b></li> <li>• <b>Fat</b></li> <li>• <b>Air or gas</b></li> </ul>	<p><b>Whitest/Most Dense</b></p>  <p><b>Blackest/Least Dense</b></p>

For example, heart tissue is denser than lung tissue. Therefore, more photons are absorbed when an x-ray beam strikes a patient's heart compared with when an x-ray beam strikes the lung next to the heart. This differential absorption makes the heart appear "whiter" on the x-ray film than the lung and allows you to see the **interface** between these two structures, as shown in *Figure 1.1a*.

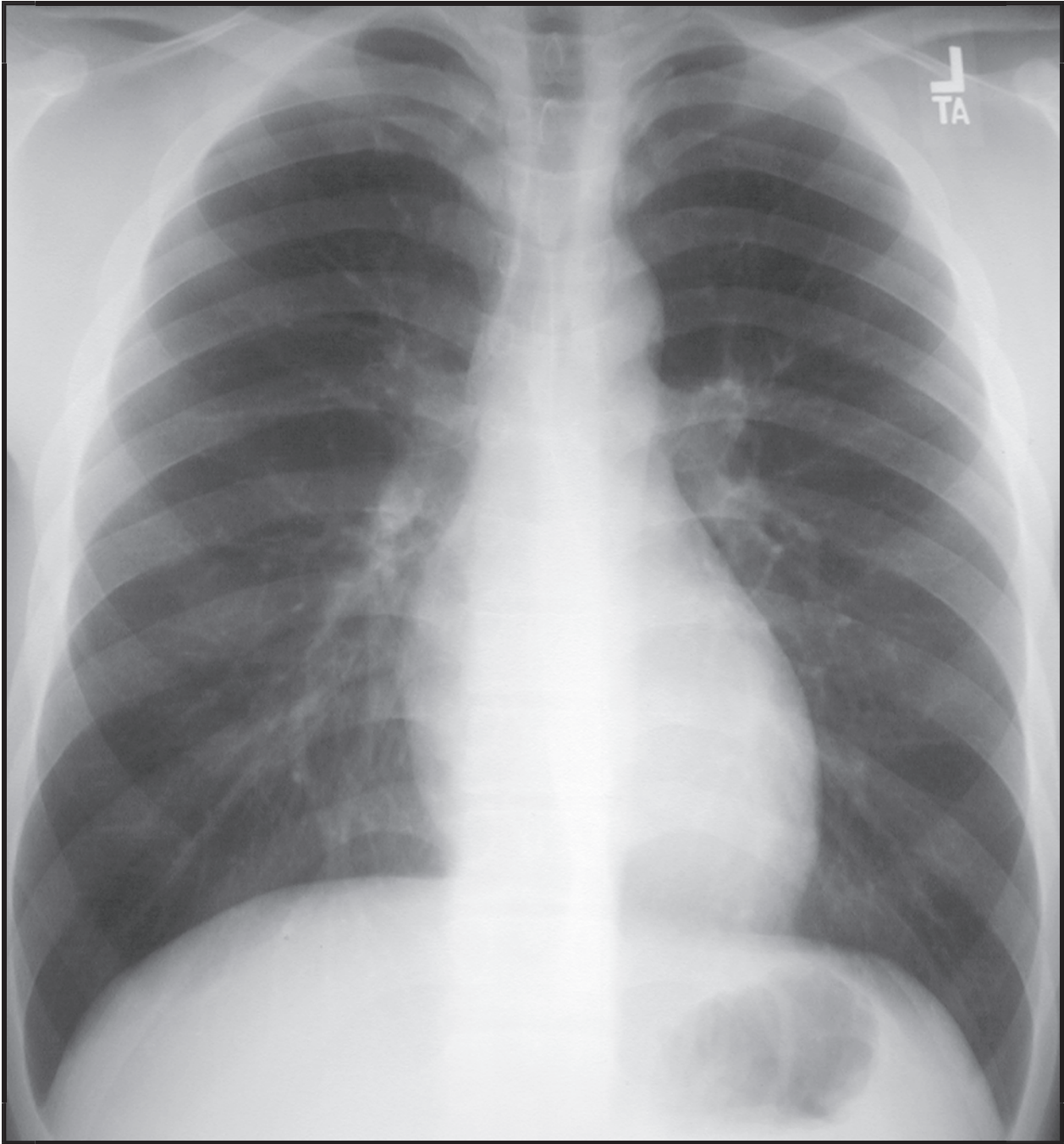
## ***Normal Contours Created by Aerated Lung***

The presence of aerated lung contacting the diaphragm and cardiomediastinal structures creates several interfaces that we normally expect to see and that should be routinely sought on every radiograph. These expected interfaces include:

1. The aerated lower lobes are in contact with the diaphragm, allowing visualization of the diaphragm.
2. The medial segment of the right middle lobe contacts and allows visualization of the lateral wall of the right atrium.
3. The aerated lingula contacts and allows visualization of the left cardiac contour.
4. The right upper lobe contacts and allows visualization of the superior vena cava.
5. The left upper lobe contacts and allows visualization of the aortic arch.

When you are familiar with these normal contours, you can correctly recognize the anatomic location of lung parenchymal abnormalities.

**Figure 1.1a: Normal Frontal Chest Radiograph**



Use the unmarked image in *Figure 1.1a* for comparison with *Figure 1.1b* on page 1-15.



## ***Basic Chest Radiographic Patterns: Normal Anatomy***

Before exploring plain radiographic patterns of disease and their differential diagnoses, it is important to be familiar with normal plain radiographic anatomy in both the frontal and lateral projections. A basic understanding of radiographic anatomy is required for accurate image interpretation.

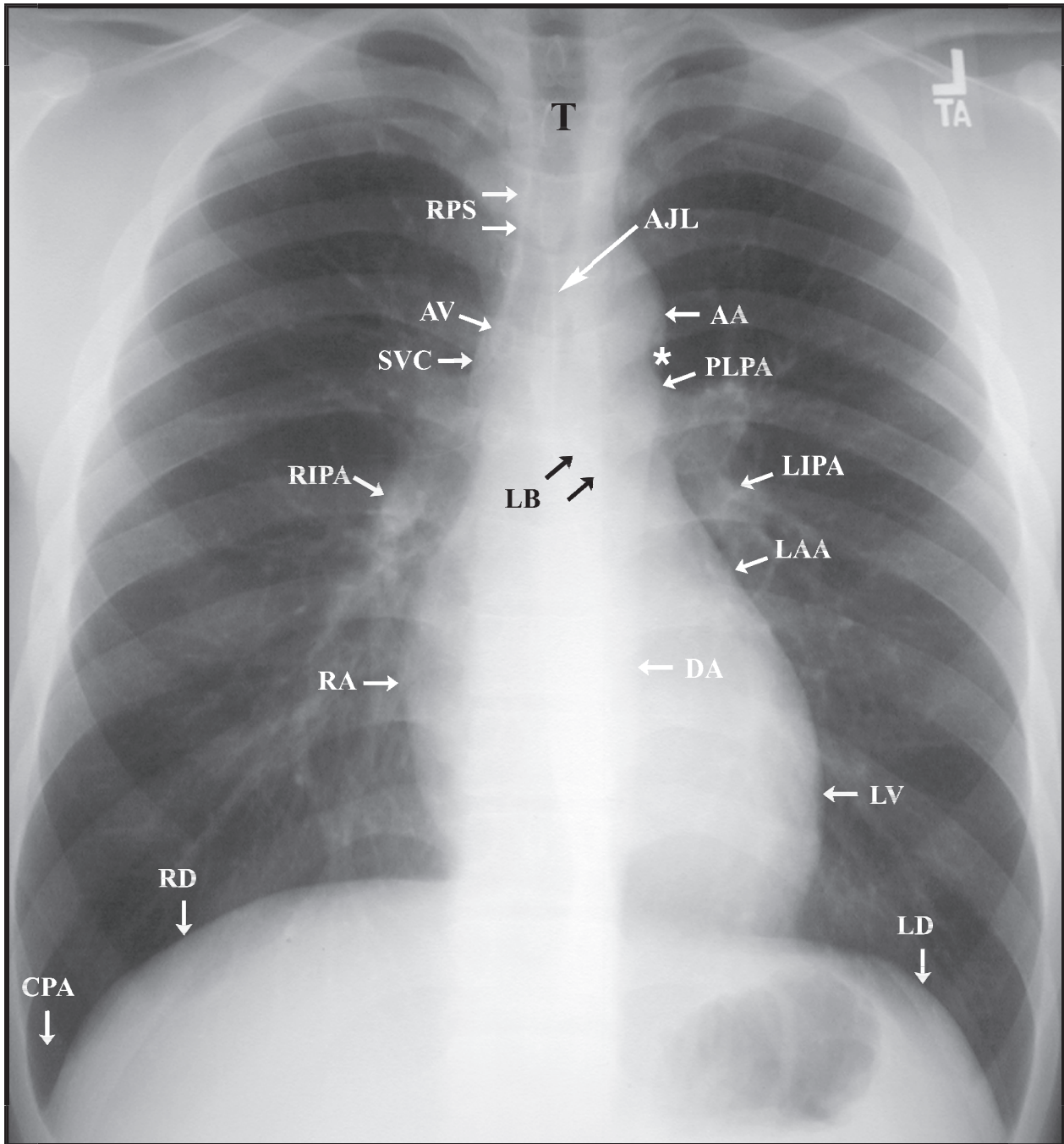
### ***Frontal Chest Radiograph***

---

On the frontal chest radiograph, several mediastinal structures are usually clearly visible and should be recognized on every examination.

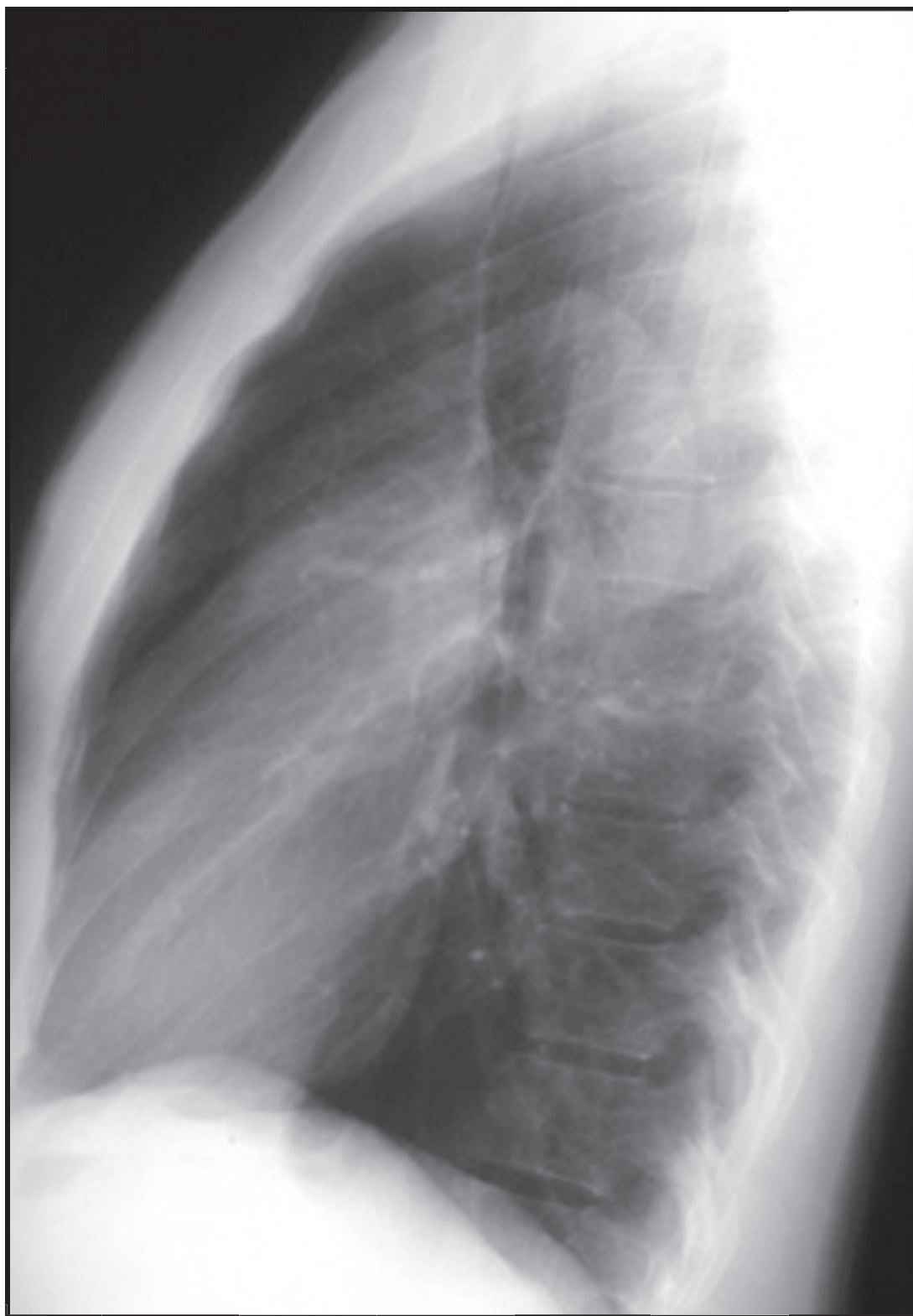The arrows on *Figures 1.1b* and *1.1d* correspond to the numbered descriptions below.

1. Superiorly, the left cardiomedial contour is dominated by the presence of the **aortic arch (AA)**. The ascending aorta may form a border along the right cardiomedial contour, particularly in older patients.
2. Because it contacts the lung as it courses inferiorly through the thorax, the left lateral wall of the **descending aorta (DA)** is usually visible.
3. Just inferior to the aortic arch, the **proximal left pulmonary artery (PLPA)** is visible in the left hilar region. In most patients, the left hilum is slightly more cranially positioned than the right. More inferiorly and laterally, the **left interlobar pulmonary artery (LIPA)** dominates the left hilum.
4. The concavity created by the overlap of the aortic arch and the left pulmonary arterial shadows is called the **aortopulmonary window (✱)**.
5. On the frontal radiograph, you can often see the **left main bronchus (LB)** just below the main pulmonary artery segment and the left pulmonary artery.
6. The region of the **left atrial appendage (LAA)** projects slightly inferior to the left main bronchus along the left cardiomedial contour. The **left ventricle (LV)** completes the rest of the left cardiomedial contour.
7. You can see the **superior vena cava (SVC)** in the most superior portion of the right cardiomedial contour. The soft tissue stripe created by the interface of the right lateral wall of the trachea and the adjacent right upper lobe is known as the **right paratracheal stripe (RPS)**.
8. Near the inferior portion of the right paratracheal stripe, nestled in the right tracheobronchial angle, you often see the **azygous vein (AV)**.
9. Just below the azygous vein is the right hilum; the **right interlobar pulmonary artery (RIPA)** may be seen exiting this region, coursing laterally and inferiorly.
10. The **right atrium (RA)** forms the right cardiac border. You may occasionally see a small shadow coursing obliquely within the right cardiophrenic angle; this shadow represents the inferior vena cava.
11. The **trachea (T)** is usually easily seen on frontal radiographs.
12. The **right diaphragm (RD)** and **left diaphragm (LD)** contours are clearly visible.
13. The lateral **costophrenic angle (CPA)** is visible in the lower left portion of the thorax in this example.
14. Occasionally, the **anterior junction line (AJL)** may be seen forming an obliquely oriented line overlying the mediastinum. The anterior junction line represents the point of contact between the two lungs anteriorly.

**Figure 1.1b: Normal Frontal Chest Radiograph**

(This page intentionally left blank)

***Figure 1.1c: Normal Lateral Chest Radiograph***



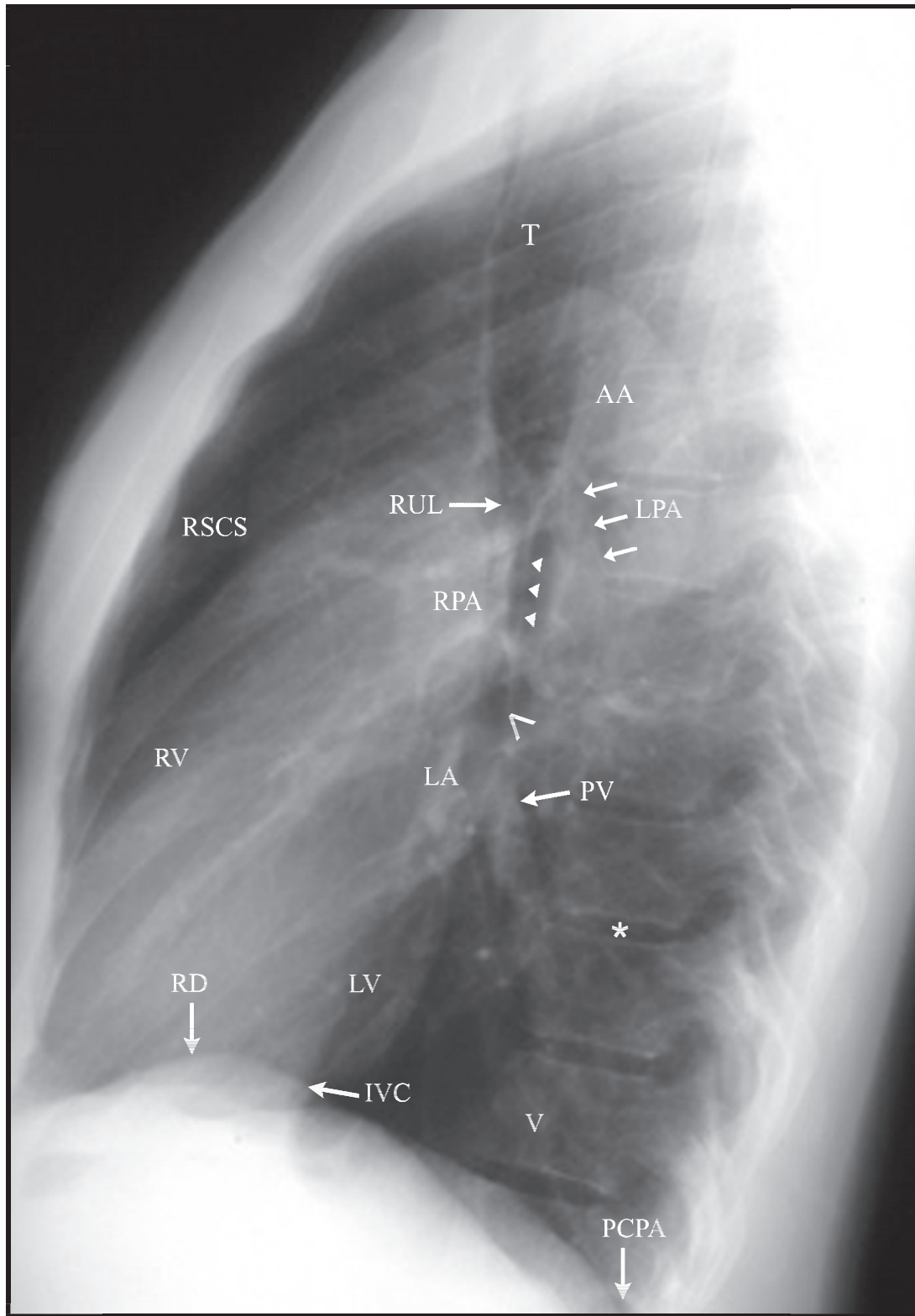
Use the unmarked image in *Figure 1.1c* for comparison with *Figure 1.1d* on page 1-19.



## ***Lateral Chest Radiograph***

---

1. On the lateral view, the **vertebral bodies (V)** and **intervertebral disc spaces (★)** are visible posteriorly.
2. Anteriorly, you will see the sternum, and the portion of lung just beneath the sternum, called the **retrosternal clear space (RSCS)**.
3. The **trachea (T)** is easily visualized on the lateral radiograph.
4. The orifice of the **right upper lobe bronchus (RUL)** appears as a circular lucency projecting over the continuation of the tracheal air column.
5. Just below the orifice of the right upper lobe bronchus, a soft tissue stripe is often visible. This stripe represents the **posterior wall of the bronchus intermedius** (arrowheads).
6. Just beneath the right upper lobe bronchus orifice, you may see a second circular lucency. This is the origin of the left upper lobe bronchus.
7. The **left pulmonary artery (LPA)** appears as a soft tissue density structure coursing over the left upper lobe bronchus.
8. The **right pulmonary artery (RPA)** is visible as a rounded soft tissue density. It is anterior and slightly inferior to the orifice of the right upper lobe bronchus.
9. An area known as the **infrahilar window (Λ)** may be seen just beneath the right pulmonary artery. Normally, this area is relatively clear; it should contain only vessels and bronchi. Unexpected contours in this region raise suspicion for adenopathy (see *Figure 1.11b* on page 1-39).
10. Just below the right pulmonary artery, the **left atrium (LA)** is visible along the posterosuperior portion of the cardiac contour. **Pulmonary veins (PV)** may be seen as tubular or nodular soft tissue densities projecting over this region.
11. More inferiorly, you see the **left ventricle (LV)**, which forms the posteroinferior cardiac contour.
12. The **right ventricle (RV)** comprises the anterior and superior portion of the cardiac contour on lateral radiographs. Right ventricular contours are rarely visible on frontal radiographs.
13. The aorta may variably be seen extending superiorly from the heart as the ascending aorta, then coursing posteriorly as the **aortic arch (AA)**, and finally coursing inferiorly as the descending thoracic aorta.
14. The **posterior costophrenic angles (PCPA)** are visible inferiorly.
15. The **right diaphragm (RD)** and left diaphragm contours are visible inferiorly.
16. The **inferior vena cava (IVC)** may occasionally be seen as a curvilinear shadow with a concave posterior border along the inferior aspect of the heart intersecting the right diaphragm.

**Figure 1.1d: Normal Lateral Chest Radiograph**

Now that you are familiar with the physical principles underlying the plain radiographic image, as well as basic roentgen anatomy, we will look at the proper terms used to characterize and localize abnormalities found on the chest radiograph. Each pattern of disease we discuss includes a specific radiographic example and its proper interpretation.

Using proper terms is essential for accurate characterization of chest abnormalities and to clearly communicate your findings to other physicians and medical staff. Accurately and precisely characterizing an abnormality on a radiograph is the basis for generating differential diagnoses.

At the most basic level, when an area of increased density (“whiter”) is apparent on a radiograph, the term “opacity” is used. Identifying an opacity does not necessarily localize the process within the lung; for example, an opacity may be parenchymal, pleural, extrapleural, or even outside the patient. After you observe an abnormal opacity, you should attempt to localize it.

In other words, you should pinpoint the location of the abnormality by localizing the opacity as:

- **Parenchymal** (within the lung)
- **Extraparenchymal** (either within the pleural space or the chest wall)
- **Mediastinal**
- **Outside the patient**

With the notable exception of artifacts on the film, any opacity seen on a chest radiograph will be located in one (or more) of the above potential locations. Accurately localizing the abnormality is fundamental to developing a reasonable differential diagnosis.

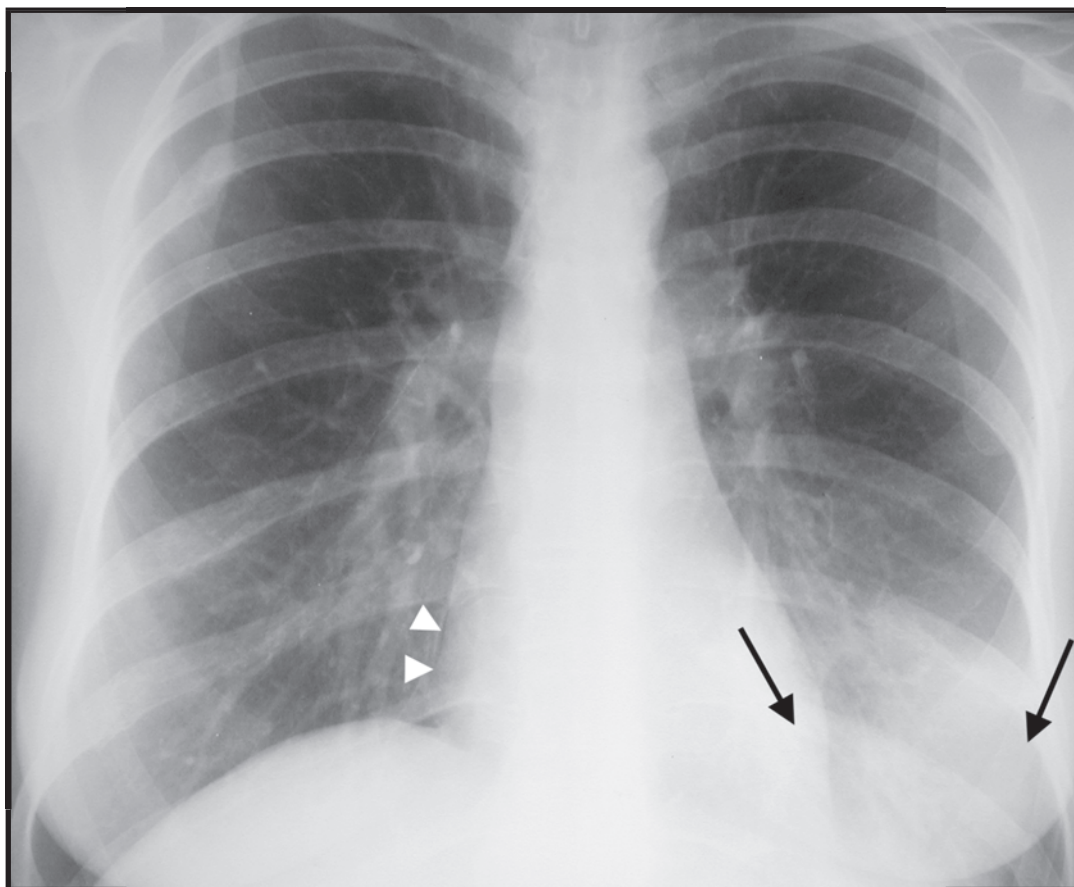
## Interfaces

If two structures of the same density are next to each other, they will not be seen as separate structures. This is because there is no density difference to create an interface. The heart is a good example. Although the heart is made up of very different tissues (blood, muscle, pericardium, etc.), all of the heart's tissues are of similar density. The heart appears as one discrete structure on plain radiographs because the x-ray beam “sees” only one density and thus one structure, as demonstrated in *Figure 1.2a*.

As you can see, the limited density range that can be discriminated by the x-ray beam is a limitation of plain radiography. However, an understanding of the concept of differential x-ray absorption allows you to accurately localize and characterize pathology on chest radiographs. How this is accomplished is illustrated by a basic plain radiographic finding known as the **silhouette sign**.

### The Silhouette Sign

**Figure 1.2a: Silhouette Sign**

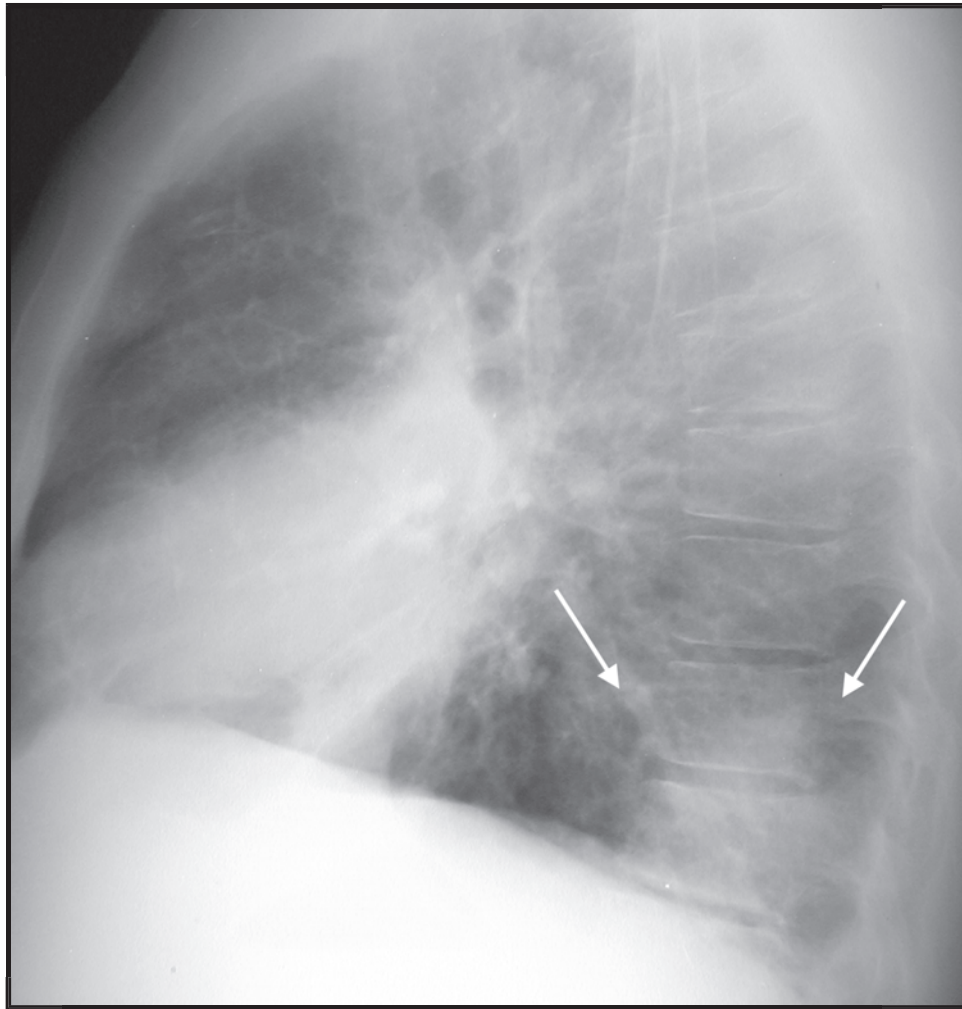


When an aerated lung contacts a structure of different density (such as the heart, mediastinum, or diaphragm), an interface is created and, under normal conditions, you would see a boundary. In *Figure 1.2a* above, the arrowheads point to the normal right heart border. This interface is created because the normally aerated lung (in this case the right middle lobe) contacts the right atrium.

When the air within the lung is replaced by another substance, such as when fluid fills the airspace (consolidated lung), the interface created by the aerated lung is lost, indicating an abnormal condition.

Consolidated lung parenchyma, whether it is due to pus, blood, tumor cells, or edema fluid, has a density similar to water, just like the soft tissue of the heart, mediastinum, and diaphragm. When the consolidated lung is adjacent to soft tissues (which have similar water density), such as the heart or mediastinum, the normal interface created by aerated lung is lost. The loss of the normal air-water density interface (when the lung becomes consolidated) has been termed the **silhouette sign**. The black arrows in *Figure 1.2a* indicates the loss of the left diaphragmatic contour due to the presence of the adjacent consolidated lung.

**Figure 1.2b: Silhouette Sign—Consolidation**



In the lateral view in *Figure 1.2b*, note that the left diaphragm contour is obscured. The loss of the normally visualized diaphragm contour is the result of consolidation within the left lower lobe caused by bronchopneumonia, indicated by the arrows.

Familiarity with the concept of differential x-ray absorption not only helps you understand the normal radiographic image but also helps you recognize pathologic alterations.



## ***Assessing the Technical Quality of Radiographic Studies***

---

Before a radiograph is interpreted, the reader should always assess the quality of the study. These technical parameters should be assessed:

- Exposure
- Proper Positioning
- Inspiratory effort

### **Exposure**

A properly exposed radiograph allows faint visualization of the thoracic spine and intervertebral disc spaces as well as clear visualization of branching vessels through the heart. If the radiograph is underexposed, it becomes difficult to “see through” the mediastinal contours and heart, and thus the lung parenchyma in these areas cannot be adequately visualized. On the other hand, if the radiograph is overexposed, the film will appear “too black.” This situation may render small lung nodules or other faint pulmonary parenchymal opacities very difficult to see. This situation may be somewhat compensated for by the use of bright illumination (a bright or “hot” light).

### **Proper Positioning**

A properly positioned radiograph shows the medial ends of the clavicles equidistantly positioned from the spinous processes of the vertebral bodies; essentially no patient rotation is present in this situation. Patient rotation does not necessarily render a radiograph uninterpretable, but it can create a confusing appearance.

The medial ends of the clavicles will usually overlie the junction of the medial ends of the first anterior ribs with the manubrium. When the clavicles are projected cranial to the first ribs, the projection is said to be lordotic. Lordotic projections can be useful for visualizing the pulmonary apices, but such projections are not desirable for routine frontal radiographs.

### **Inspiratory Effort**

Full inspiration in normal patients usually results in the diaphragm projecting over the level of the tenth posterior ribs. When the diaphragm is projected below the eleventh posterior ribs, the lung volumes are usually considered abnormally large. This situation may reflect air trapping or obstructive pulmonary disease. When the diaphragm projects near or above the eighth posterior ribs, the lung volumes are abnormally low. This situation may reflect poor inspiratory effort or restrictive lung disease.

Low lung volumes often result in basilar vascular crowding and atelectasis and may create the appearance of interstitial lung disease or pneumonia in the lung bases. Additionally, low lung volumes often create the appearance of cardiac enlargement. Caution must be exercised when interpreting radiographs with low lung volumes because significant disease can easily be overlooked, or the radiograph may be overinterpreted in this setting.

## ***Chest Radiograph Interpretation: Basic Patterns of Disease***

In the following section, we will discuss the appearance of basic patterns of disease on the chest radiograph. We will discuss how to use proper terminology to describe radiographic abnormalities and how proper terminology allows you to correctly localize abnormal processes and generate accurate differential diagnoses. The basic patterns of disease visible on plain radiography and the acceptable terms to describe these disease patterns are as follows:

- **Consolidation** (or airspace filling)
- **Interstitial** (including linear and reticular opacities, small well-defined nodules, miliary patterns, and peribronchovascular thickening)
- **Solitary nodule**
- **Mass**
- **Lymphadenopathy**
- **Cyst/cavity**
- **Pleural abnormalities**

The remainder of this chapter will review these patterns in detail. Although you will occasionally encounter cardiomedial contour abnormalities and abnormalities of the osseous and soft tissue structures, they are beyond the scope of this work. The interested reader is referred to several excellent books and publications concerning chest radiograph interpretation listed at the end of this chapter.

When interpreting radiographs, it is important to understand that more than one of the above patterns may be present *simultaneously*. Such radiographs can be quite challenging to interpret. You should attempt to synthesize multiple patterns into a single diagnosis when possible.

For example, the combination of a pulmonary nodule, an ipsilateral pleural effusion, and adenopathy is suggestive of bronchogenic carcinoma with nodal (and perhaps pleural) metastases. Occasionally it is simply not possible to combine several disease patterns into a single, unifying diagnosis.

Under such circumstances, it is often best to generate a differential diagnosis based on the dominant disease pattern present.

## ***Consolidation (Airspace Opacity)***

---

Consolidation appears as a confluent, ill-defined opacity, effacing the normal shadows created by pulmonary blood vessels, and often displaying a tendency to extend to pleural surfaces (*Figure 1.3*, indicated by the obscured right diaphragm). Consolidation occurs when air within the pulmonary parenchyma is replaced by another substance, such as blood, pus, water (i.e., edema), or tumor cells.

### **Air Bronchograms**

An air bronchogram may be seen when consolidation is present. An air bronchogram is a manifestation of the basic principle of differential x-ray absorption. Normally, air within bronchi is not visible because normal bronchi are surrounded by aerated lung. When the alveoli are rendered airless, or consolidated, bronchi become visible because the air within them is now contrasted with surrounding fluid density within the lung parenchyma. The air bronchogram is a fundamental sign of consolidation, or airspace filling, and confidently localizes an opacity on the chest radiograph as within the lung parenchyma.

### **Acinar Shadow**

Another indication of airspace filling or consolidation, acinar shadows appear as ill-defined 4 to 8 mm opacities, presumed to represent opacification of the individual pulmonary acini. Multiple acinar shadows create the confluent, ill-defined opacity characteristic of consolidation described above.

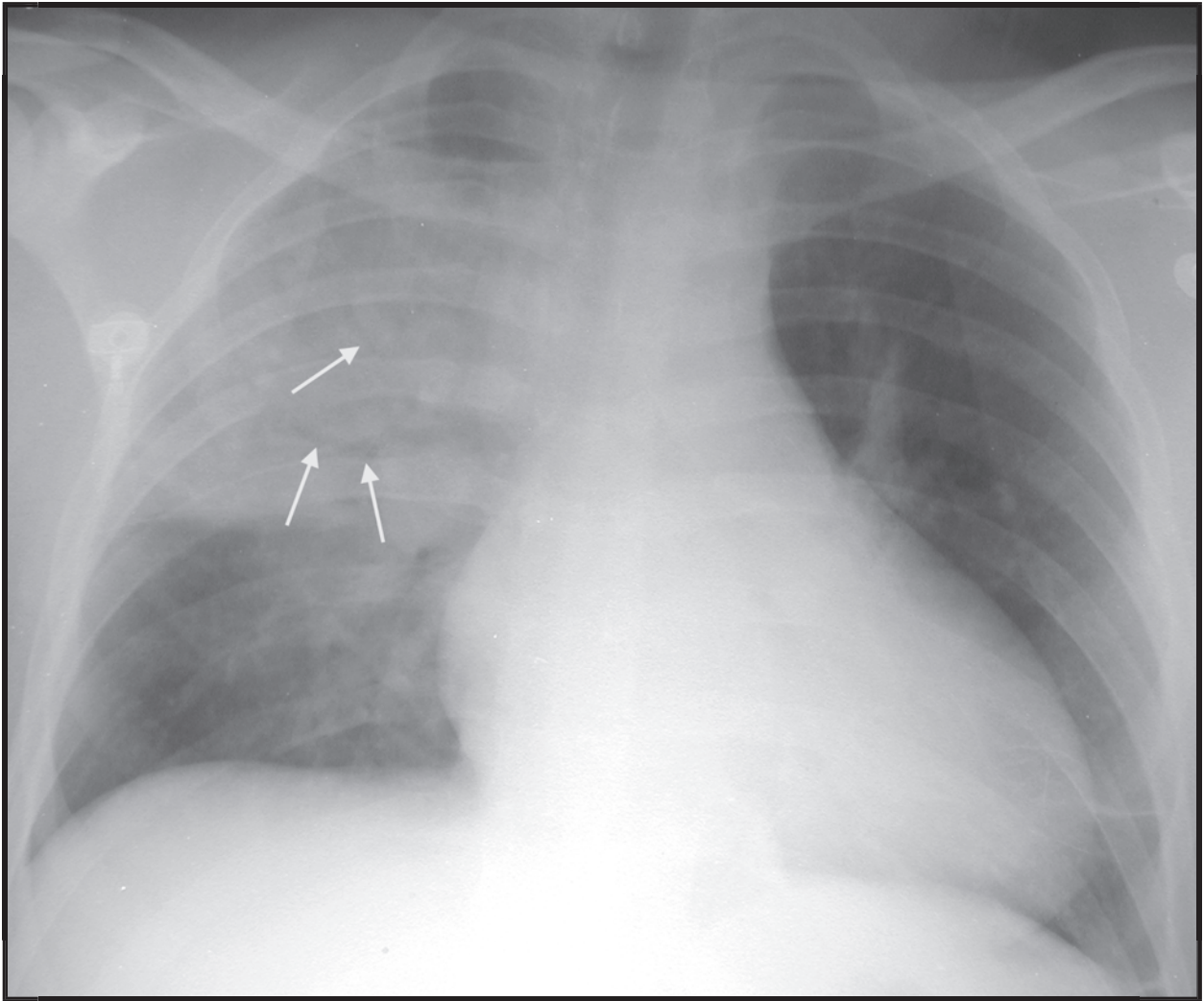
### ***Key Points***

- Consolidation represents an airless lung; it occurs when air in the lung parenchyma is replaced by some other substance such as pus, blood, edema, or tumor cells.
- The air bronchogram is created when the consolidated lung surrounds air-filled bronchi, causing these bronchi to be visible.



## ***Consolidation (Airspace Opacity)***

***Figure 1.3: Basic Features of Consolidation, or Airspace Opacity*** (also see Figure 1.2a and 1.2b)



### ***Diagnosis***

Right upper lobe pneumonia. Air bronchograms (arrows) are visible.

## ***Interstitial Opacity: Linear and Reticular Opacity, Nodules, Miliary Pattern, and Peribronchovascular Thickening***

---

Linear opacities, septal lines, reticular opacities, peribronchovascular thickening, nodules, and the miliary pattern are radiographic manifestations of interstitial lung disease. These patterns suggest a disease process localized to the pulmonary interstitium, as opposed to the airspace, and lead to specific differential diagnoses.

### **Linear Opacity: Septal Lines**

- Occasionally, thin, 1–3 mm thick, straight lines, 1.5–2 cm in length, and perpendicular to the pleural surface, may be visible on radiographs. These opacities are called septal lines, or Kerley's B lines, and they represent thickening of the interlobular septae.
- When these lines are 1–2 mm thick, 2–6 cm in length and extend from the hilum toward the periphery, they may be called Kerley's A lines. These structures also represent thickened interlobular septae.

### **Reticulation**

Reticulation refers to the multiple tiny lines that intersect each other at several angles, creating a netlike pattern on the chest radiograph.

### **Nodules**

This term may be applied to opacities that are roughly circular, 2–30 mm in diameter, usually with fairly discrete borders. Nodules may be a manifestation of interstitial lung diseases, although they are not exclusively seen with diseases affecting the pulmonary interstitium. The term “mass” may be used when the nodule exceeds 30 mm in size.

### **Miliary Pattern**

This term refers to numerous small nodules, approximately 2–3 mm in diameter, that are well-defined and diffuse in distribution.

### **Peribronchovascular Thickening**

This is a qualitative term that refers to an increase in thickness of the bronchovascular bundles as they course peripherally from the hila. Any process that affects the following structures and the connective tissue surrounding these structures may result in peribronchovascular thickening:

- Bronchial walls
- Bronchial mucosa
- Pulmonary arteries and veins
- Lymphatics

The term “peribronchovascular thickening” is a subjective descriptor that requires a fair amount of experience to apply accurately.

## Linear Opacities

**Figure 1.4: Linear Opacity**

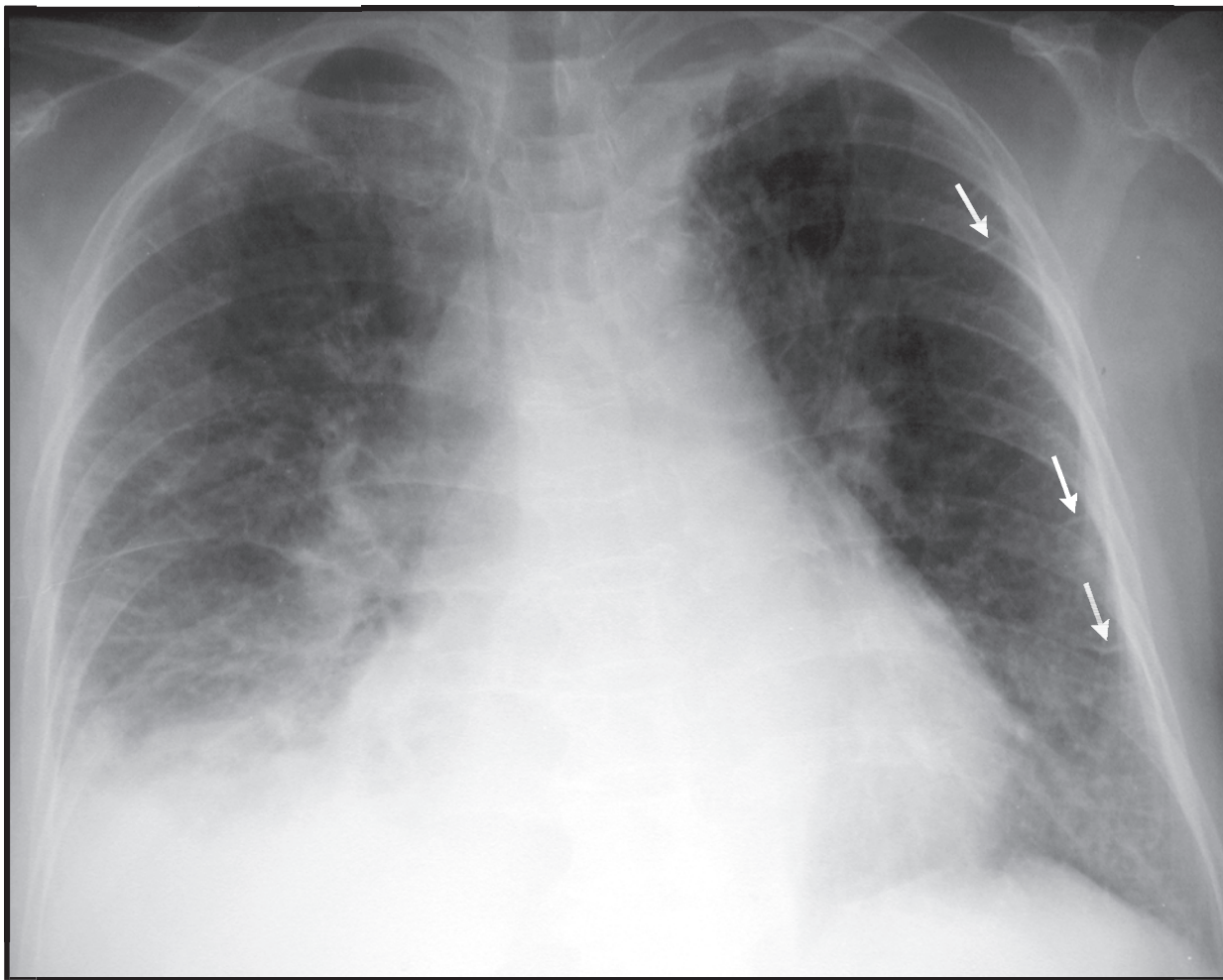


Figure 1.4 demonstrates numerous abnormalities but one feature in particular is characteristic of interstitial opacity: septal lines or Kerley's B lines (arrows).

### Key Points

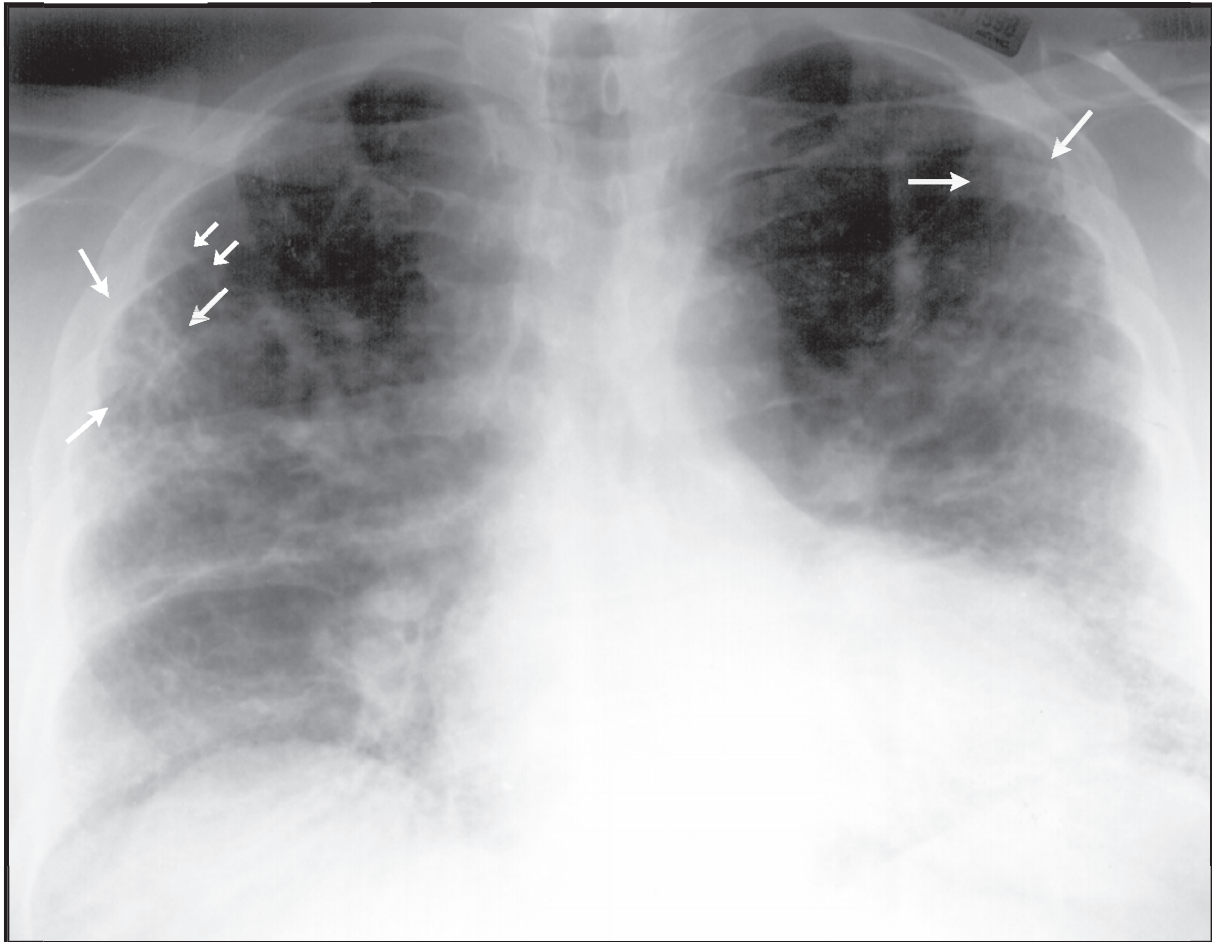
- Kerley's B lines are thin, linear opacities perpendicular to the pleural surface. In this radiograph, they are best visualized in the lateral portion of the thorax.
- Kerley's B lines represent thickening of the interlobular septae.

### Diagnosis

Congestive heart failure

## Reticulation

**Figure 1.5: Reticulation**



*Figure 1.5* demonstrates features consistent with an interstitial lung process. Note the basal and peripheral distribution and low lung volumes. Specific features visible are:

- Linear opacity (small double arrows)
- Reticular opacity (single arrows)
- Diminished lung volumes
- Basal and peripheral distribution

### Key Point

- The reticular opacity is the result of many intersecting lines (or linear opacities), creating a netlike pattern. In *Figure 1.5*, this pattern is most readily appreciated peripherally, in the regions outlined by arrows.

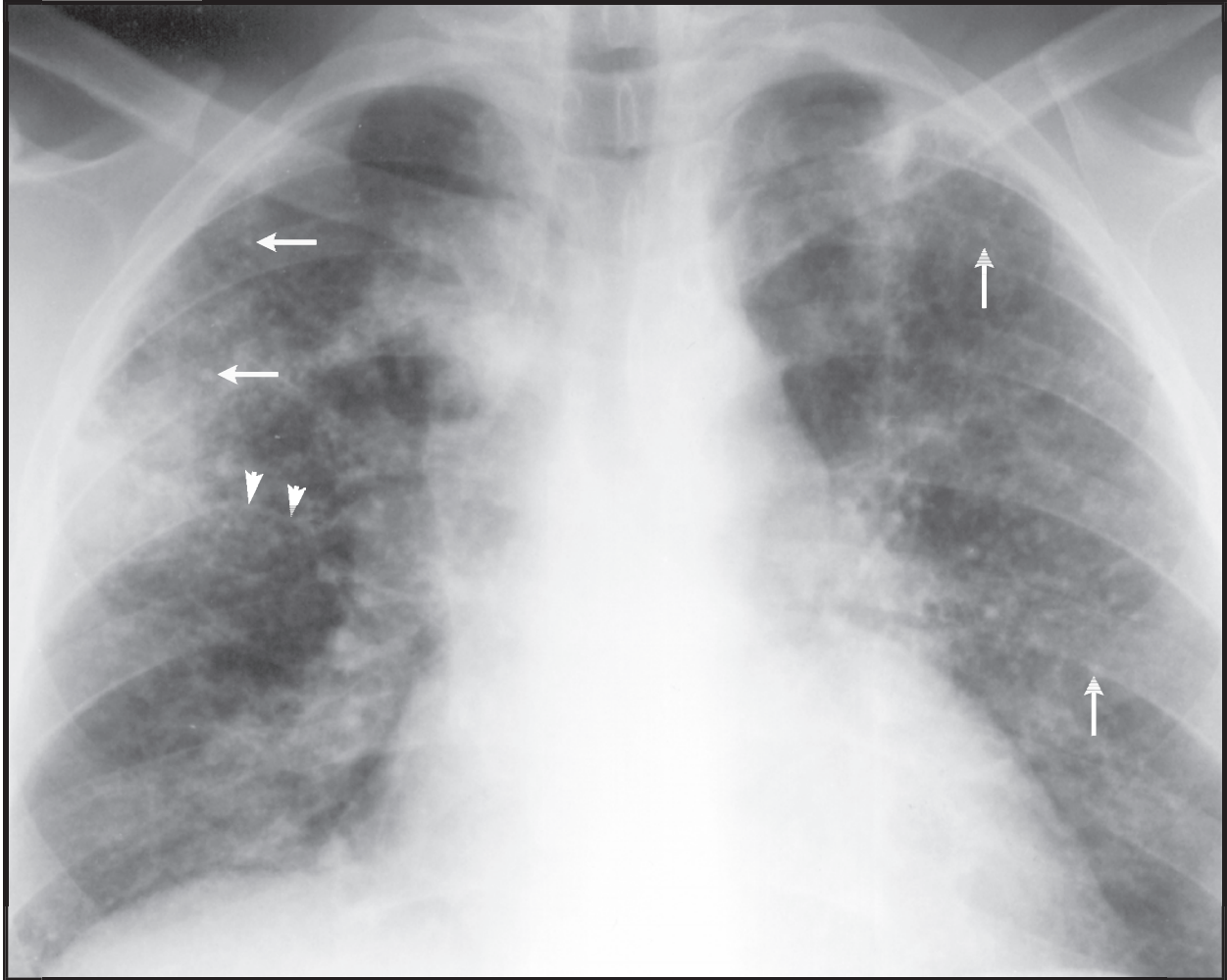
### Diagnosis

Idiopathic pulmonary fibrosis



## Nodules

**Figure 1.6: Nodules**



*Figure 1.6* demonstrates features characteristic of interstitial opacity:

- Nodules—small, discrete, with an upper lung predominance (arrows)
- Linear opacity (arrowheads)

### **Key Point**

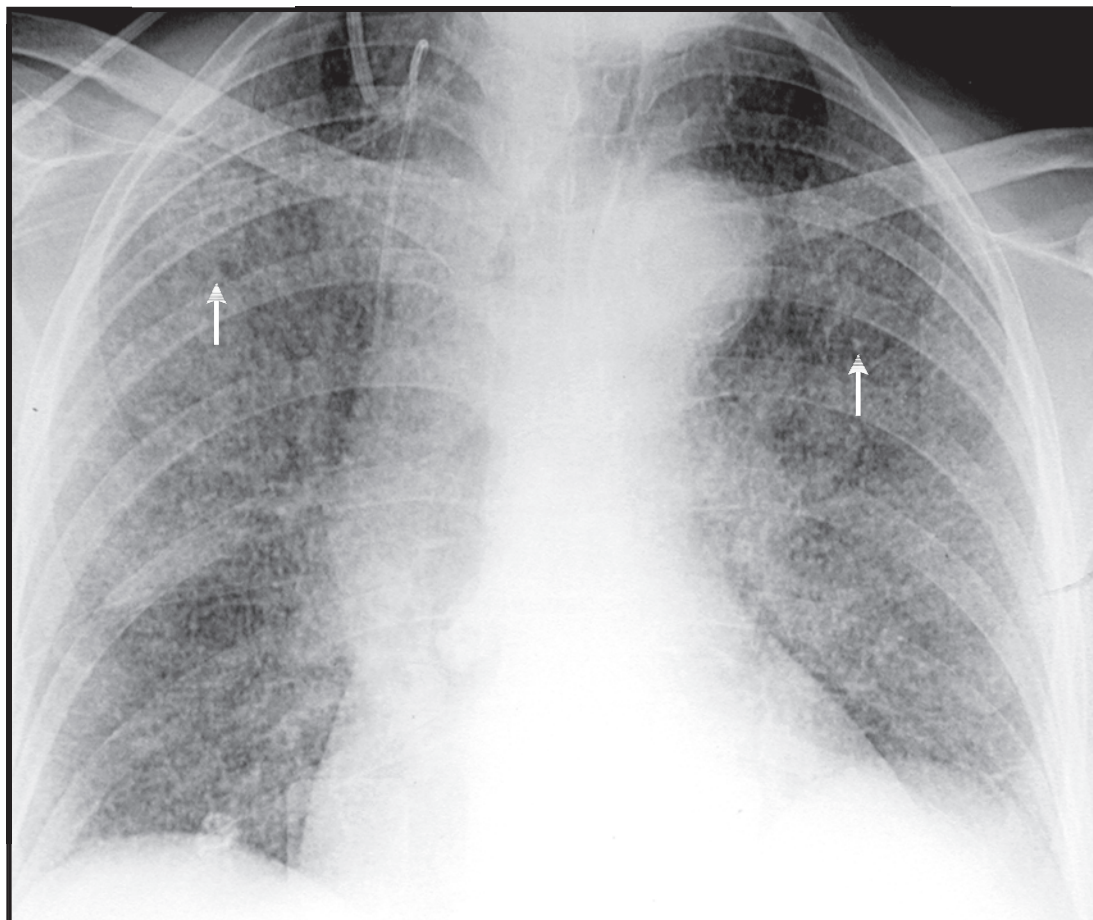
- The mid- and upper-lung predominance of small nodules, in combination with linear abnormalities, is highly suggestive of sarcoidosis, a common interstitial process.

### **Diagnosis**

Sarcoidosis

## ***Miliary Pattern***

***Figure 1.7: Miliary Pattern***



*Figure 1.7* demonstrates characteristics suggestive of an interstitial process:

- Small, well-defined nodules (arrows) scattered diffusely throughout the lung parenchyma, representing a miliary pattern

### ***Key Points***

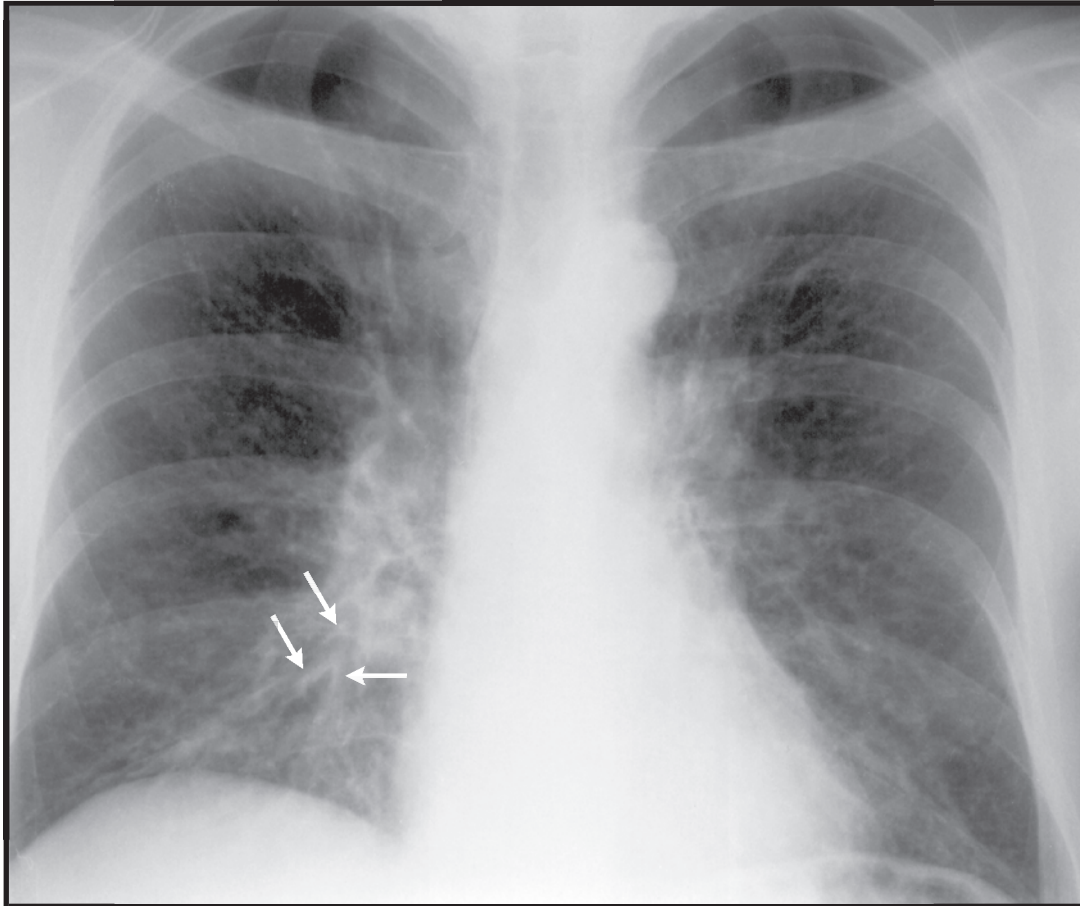
- The presence of small, well-defined nodules, approximately 2–3 mm in diameter and scattered diffusely throughout the lung parenchyma, is characteristic of a miliary pattern.
- While tuberculosis is a common cause of miliary nodules, other etiologies such as fungal disease, metastatic disease, pneumoconiosis, and sarcoidosis, may result in this pattern.

### ***Diagnosis***

Miliary tuberculosis

## ***Peribronchovascular Thickening***

***Figure 1.8: Peribronchovascular Thickening***



*Figure 1.8* demonstrates features of interstitial opacity:

- Thickening of the bronchovascular bundles as they course inferiorly from the hila (arrows)

### ***Key Point***

- Peribronchovascular thickening is another type of interstitial opacity that occurs when the bronchovascular structures emanating from the hila appear thickened. This may be due to disease infiltration along bronchial walls, inflammatory processes involving the mucosa of the bronchi, thickening of the connective tissue framework of the lung (the pulmonary interstitium), or pathologic alterations of pulmonary vessels themselves.

### ***Diagnosis***

Pulmonary Kaposi's sarcoma

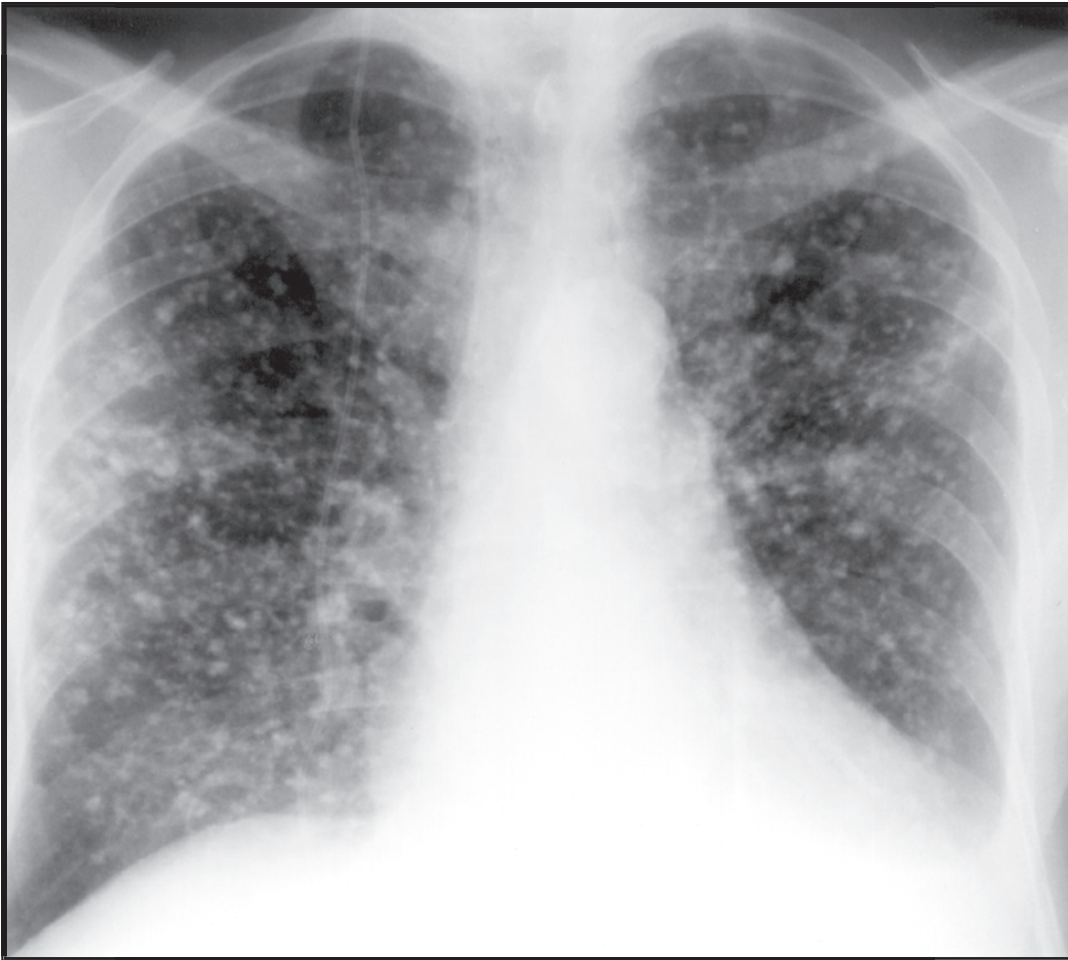## ***Self-Check One***

The following self-check will help you assess your understanding of the previous material.

After completing the self-check, look at the answers on page 1-52. Review the subjects in the previous pages to clarify any answers you have missed.

**1.** The radiograph in *Figure 1.9* displays which of the following abnormalities?

***Figure 1.9***



- A.** Peribronchovascular thickening
- B.** Small nodules
- C.** Reticulation



## ***Self-Check One (continued)***

Match the terms with the definitions. Write the letter of the term next to its correct definition. One of the items is not defined.

☐

- 2.** A particular type of nodule, approximately 2 mm in diameter with well-defined borders, diffusely distributed throughout the lungs.

☐

- 3.** Multiple tiny lines that intersect each other at several angles, creating a netlike pattern on the chest radiograph.

☐

- 4.** Commonly seen in the subpleural regions of the inferior and lateral lung, thin lines perpendicular to the pleural surface representing thickened interlobular septae.

☐

- 5.** Opacity that occurs outside the airspace but within the connective tissue framework of the lung.

☐

- 6.** The loss of the normal air-water density interface that occurs when the lung becomes consolidated.

**A.** Interstitial opacity

**B.** Reticulation

**C.** Septal lines

**D.** Silhouette sign

**E.** Miliary pattern

**F.** Mass

## ***Chest Radiograph Interpretation: Other Radiographic Patterns of Disease***

Use of the proper terminology not only accurately characterizes lesions but also necessarily evokes differential diagnostic possibilities. In addition to the patterns of consolidation (airspace filling) and interstitial opacities described above, there are many other radiographic patterns of disease. You need to be familiar with these other patterns for proper disease characterization. These additional patterns will be discussed in the broad categories below:

- Nodules and masses
- Adenopathy
- Cysts and cavities
- Pleural disease
- Cardiomeastinal contour abnormalities
- Soft tissue and osseous abnormalities

### ***Nodules and Masses***

---

#### **Nodules**

A nodule is a discrete opacity on a chest radiograph measuring 2–30 mm in diameter. The description of a nodule should be qualified with respect these factors:

- Number
- Size
- Border characteristics
- Location
- Presence or absence of calcification

You have learned about nodules as manifestations of interstitial opacities. However, there is often significant overlap between the radiographic appearances of interstitial and airspace opacities. Nodules often represent a primary airspace disease process, particularly when the nodules are inflammatory in etiology. Also keep in mind that both airspace disease and interstitial abnormalities may coexist.

Correct characterization often depends on integration of the patient's clinical history as well as on the overall pattern on the chest radiograph. For example, if linear opacities accompany a nodule, then an interstitial process may be most likely; when nodules are seen in conjunction with consolidation, an airspace etiology may be more likely.

#### **Masses**

Masses are similar to nodules in many respects. The term “mass” is used when the discrete opacity on the radiograph is greater than 30 mm in diameter. Masses may occur with airspace disease, interstitial disease, or both. As with nodules, masses should be characterized with regard to number, size, border characteristics, location, and presence or absence of calcification.

## Mass

**Figure 1.10: Mass**

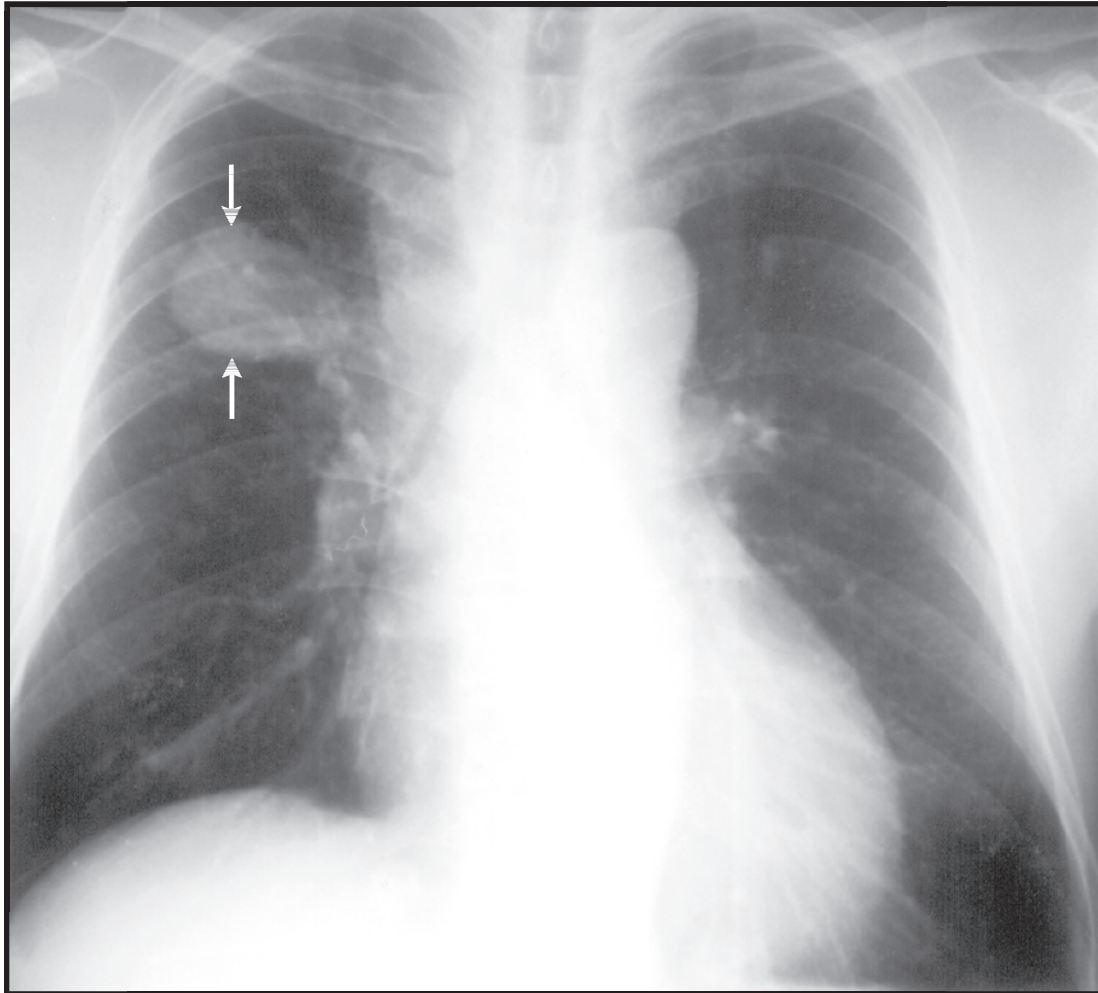


Figure 1.10 demonstrates a right upper lobe pulmonary mass—a solitary circumscribed area of increased density measuring greater than 30 mm in diameter (arrows).

### Key Points

- Nodules and masses are discrete areas of increased lung opacity whose borders do not conform to anatomic divisions (such as a fissure).
- Masses are similar to nodules except that they are larger, measuring greater than 30 mm in diameter.
- Nodules and masses should be described by noting their size, the sharpness of their borders, their number, their location, and the presence or absence of calcification.

### Diagnosis

Bronchogenic carcinoma

## ***Lymphadenopathy***

---

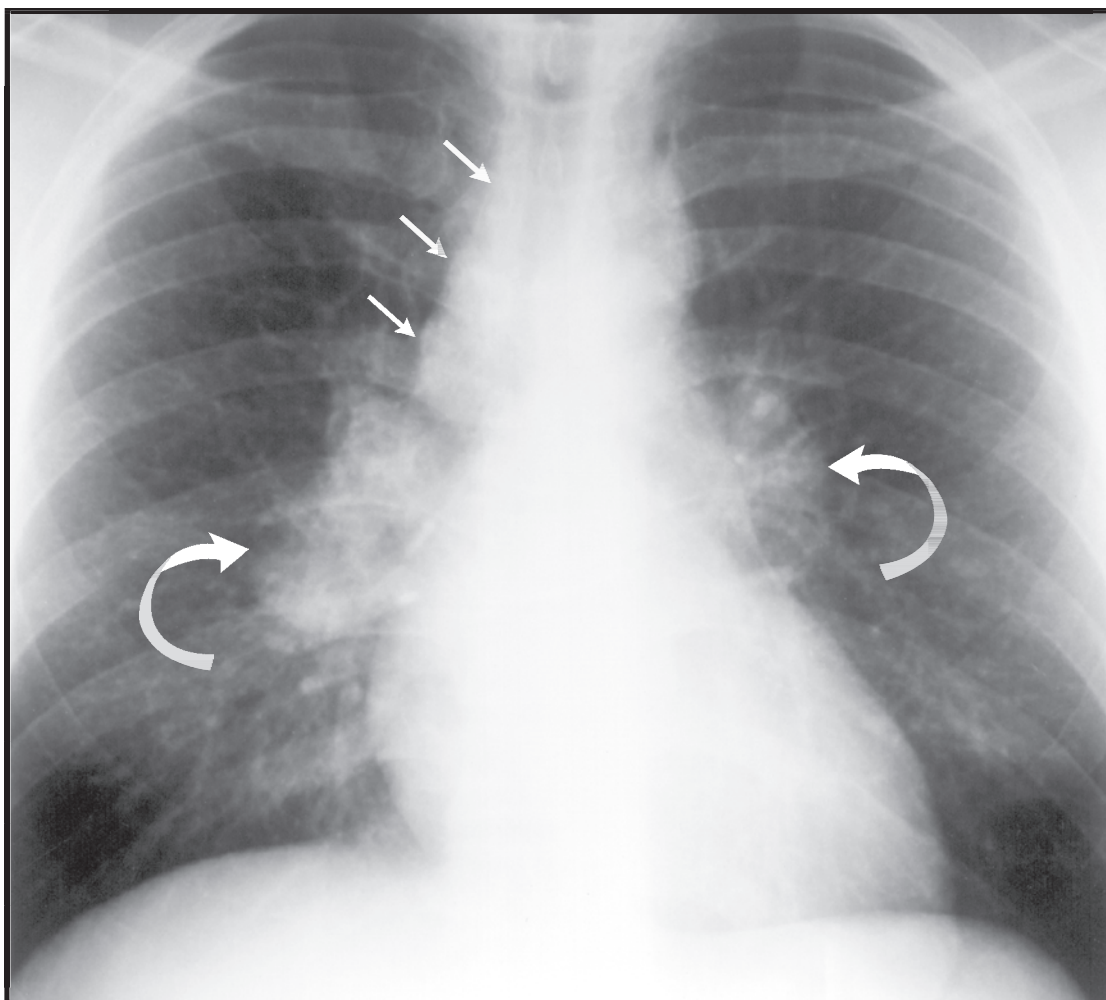
Enlarged lymph nodes appear on the chest radiograph as soft tissue densities in characteristic locations. These locations include:

- Right paratracheal area
- Hila
- Aortopulmonary window
- Subcarinal region
- Superior mediastinum
- Supraclavicular area
- Paraspinous region
- Retrosternal area on the lateral radiograph (internal mammary lymphadenopathy)

One or more regions may be involved, and, in certain conditions, nodes may calcify. Differential diagnosis depends on the presence of other features on the radiograph and the clinical context.

## ***Lymphadenopathy***

***Figure 1.11a: Lymphadenopathy on Frontal Chest Radiograph***



*Figure 1.11a* demonstrates the following:

- Right paratracheal stripe thickening (straight arrows)
- Bilateral lobular hilar enlargement (curved arrows)

### ***Key Points***

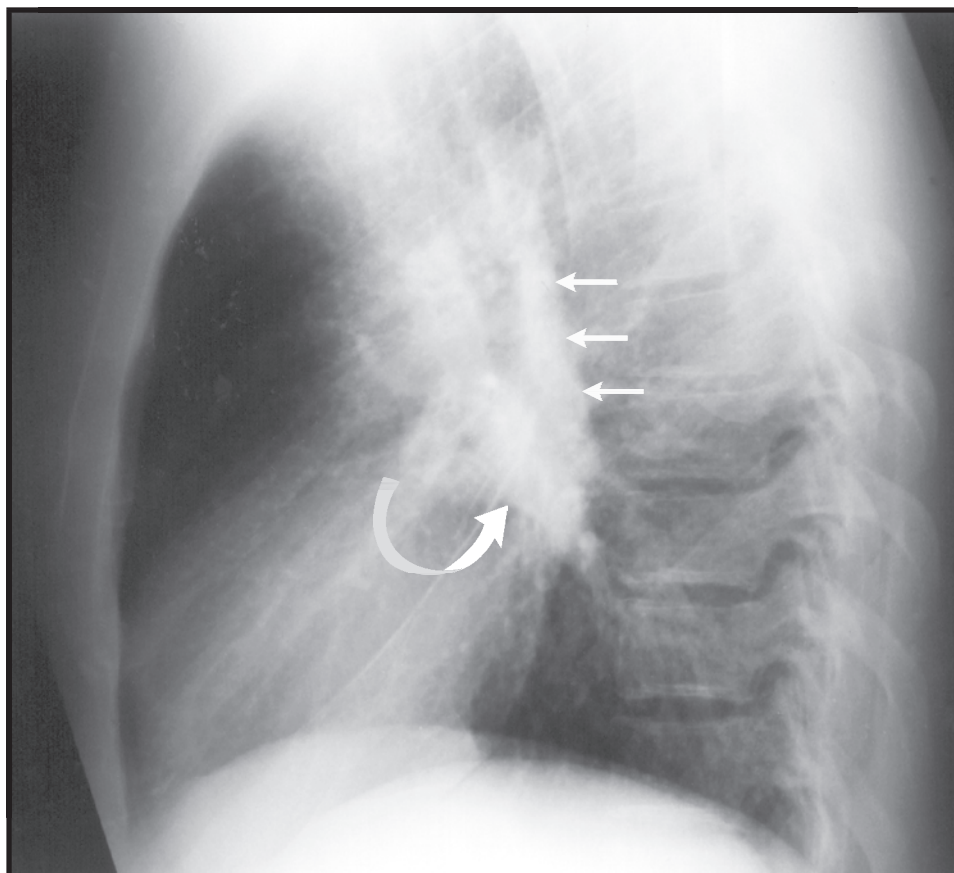
- An abnormal opacity in the right paratracheal region can be seen with intrathoracic goiter, tortuous vasculature, and adenopathy, among other less common causes.
- Hilar enlargement may be due to adenopathy, although vascular enlargement with pulmonary arterial hypertension may result in a similar appearance.
- Hilar enlargement due to pulmonary arterial hypertension is often smooth.
- Hilar enlargement due to adenopathy is frequently lobular.

### ***Diagnosis***

Sarcoidosis

## ***Lymphadenopathy***

***Figure 1.11b: Lymphadenopathy on Lateral Chest Radiograph***



*Figure 1.11b* demonstrates the following:

- Abnormal soft tissue opacity inferior to the right pulmonary artery, filling the normally clear area known as the infrahilar window (curved arrow)
- Increased thickness of the posterior wall of the bronchus intermedius and lower lobe bronchi (small arrows); compare with the normal lateral chest radiograph in *Figure 1.1d*, page 1-19

### ***Key Points***

- Lymphadenopathy is often best visualized on the lateral radiograph, when it fills the normally clear infrahilar window with an unexpected contour. This fact underscores the need for a thorough understanding of basic anatomy on this view.
- Thickening of the posterior wall of the bronchus intermedius may be due to lymphadenopathy, tumor, or edema.

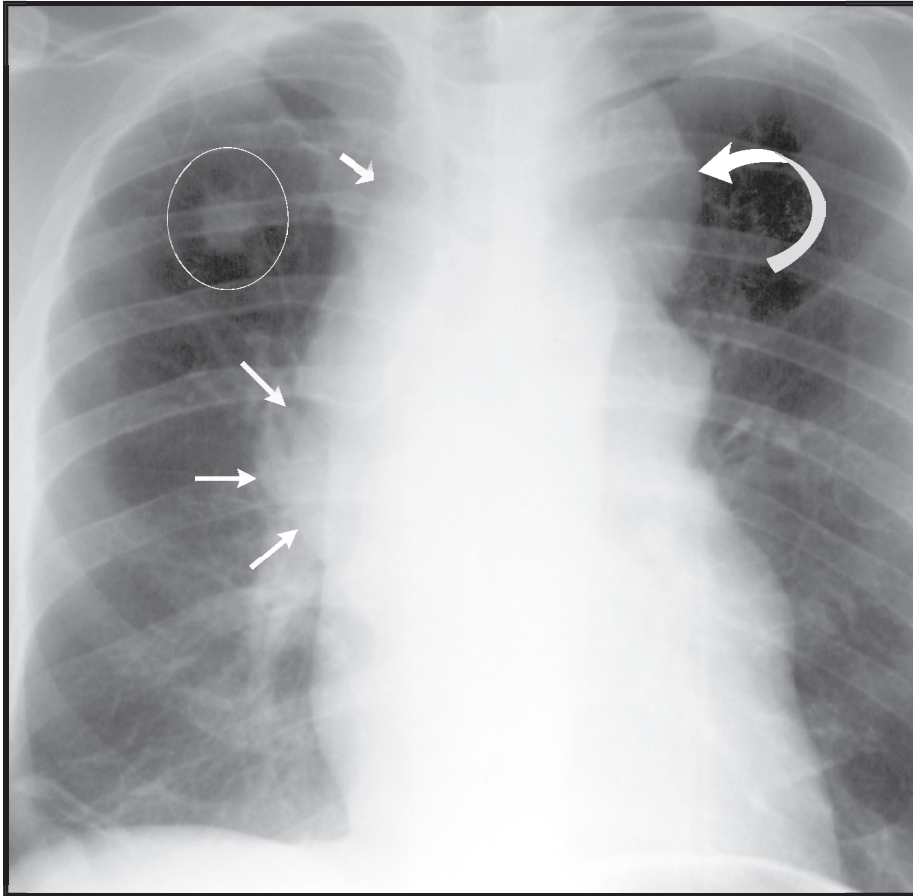
### ***Diagnosis***

Sarcoidosis



## ***Mediastinal Lymphadenopathy***

***Figure 1.12: Mediastinal Lymphadenopathy***



*Figure 1.12* demonstrates an unexpected contour medial to the right interlobar pulmonary artery (straight arrows). The right paratracheal stripe is widened (short thick arrow), and an abnormal contour is seen along the left aspect of the mediastinum in the region of the aortic arch (curved arrow). In this radiograph you can see:

- Abnormal right and left cardiomedastinal contours
- A right upper lobe nodule (circle)

### ***Key Points***

- The appearance of the abnormal contour along the right aspect of the mediastinum (straight arrows) is characteristic of lesions in the subcarinal region; such lesions include lymphadenopathy and bronchogenic cysts.
- The abnormal left mediastinal contour is created because abnormal soft tissue opacity within the mediastinum is forming a border with the adjacent lung, creating a new, unexpected contour (curved arrow). This is how mediastinal lymphadenopathy becomes visible on the chest radiograph.

### ***Diagnosis***

Mediastinal adenopathy and lung nodule from small cell lung carcinoma

## ***Cysts and Cavities***

---

Pulmonary cysts and cavities manifest as focal lucent areas on chest radiographs and may be simplistically thought of as “holes in the lung.”

### **Pulmonary Cysts**

Pulmonary cysts are focal pulmonary parenchymal spaces that do not contain lung but that are filled with either air or fluid or both. They may be congenital or acquired. Usually they have thin walls, which may be composed of cellular elements.

### **Pulmonary Cavities**

Pulmonary cavities are areas of pulmonary parenchymal space that do not contain lung but that are filled with either air or fluid or both. Cavities are created by tissue necrosis within a nodule or mass, and they become air-filled when the necrotic elements are expelled into the tracheobronchial tree.

Pulmonary cysts and cavities are characterized by noting:

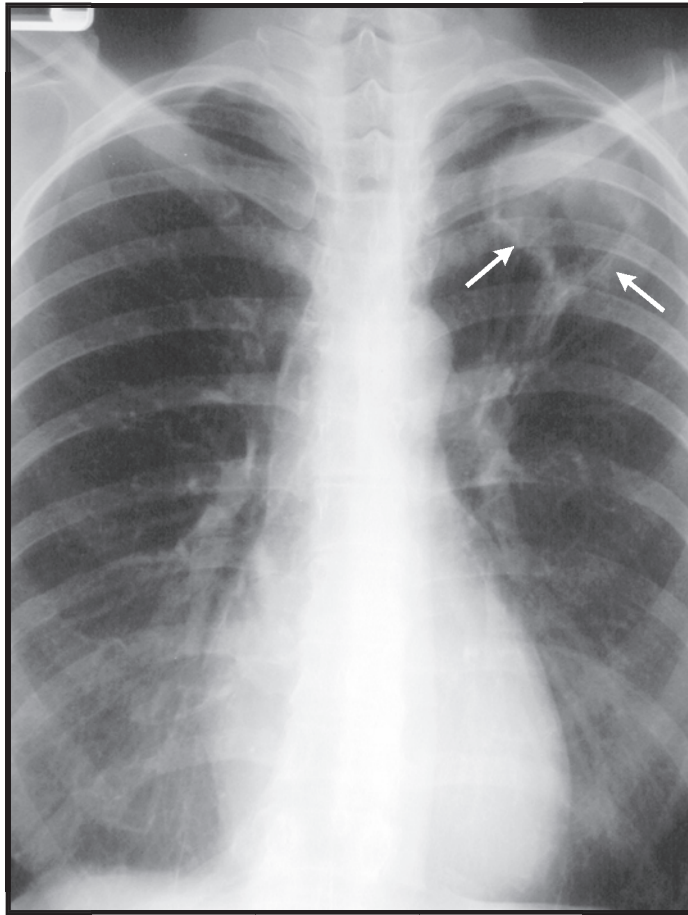
- their distribution
- their number
- the character of the inner lining
- the thickness of the wall (at the thickest portion, not including air-fluid levels) and
- the nature of the contents of the lesion.

Other causes of focal lucent areas on the chest radiograph include bronchiectasis and emphysema.



## ***Pulmonary Cysts and Cavities***

***Figure 1.13: Cavity Due to Squamous Cell Carcinoma***



*Figure 1.13* demonstrates localized lucent area in the left lung apex (arrows). A pulmonary cavity is a circumscribed lucent area within the lung containing air and/or fluid, surrounded by a wall of variable thickness resulting from necrosis of pulmonary parenchyma.

### ***Key Points***

- Focal lucent areas within the lung may result from cavities, cysts, emphysema, and bronchiectasis.
- Pulmonary cysts differ from cavities in that cavities are created by necrosis of lung parenchyma, whereas true cysts are formed by other means.
- Pulmonary cavities may result from infection, neoplasm, and infarction.
- Pulmonary cysts commonly result from infections, trauma, or toxic ingestion, as well as other rare etiologies.

### ***Diagnosis***

Squamous cell lung carcinoma

## ***Pleural Disease***

---

Pleural disease has many manifestations. Probably the most common and familiar form is pleural effusion.

### **Pleural Effusion**

Effusions may be first detected on lateral radiographs as blunting of the posterior costophrenic angles. Effusions have many appearances on chest radiographs, ranging from such blunting of the costophrenic angle to complete opacification of an entire hemithorax, with mass effect on the cardiomedial silhouette.

### **Pleural Thickening**

Occasionally pleural diseases may manifest nonspecifically as thickening. Thickening is revealed by the nondependent (nonlayering) nature of the opacity on decubitus radiographs. Nodular pleural thickening may suggest malignancy. The risk of malignancy is incrementally increased by the presence of any of the following patterns:

- is nodular
- is greater than 1 cm
- involves the entire circumference of the hemithorax
- involves mediastinal and/or fissural pleural surfaces or
- is accompanied by volume loss.

### **Calcification**

Pleural processes may calcify, particularly in prior tuberculous empyemas, prior hemothoraces, and asbestos-related pleural disease.

---

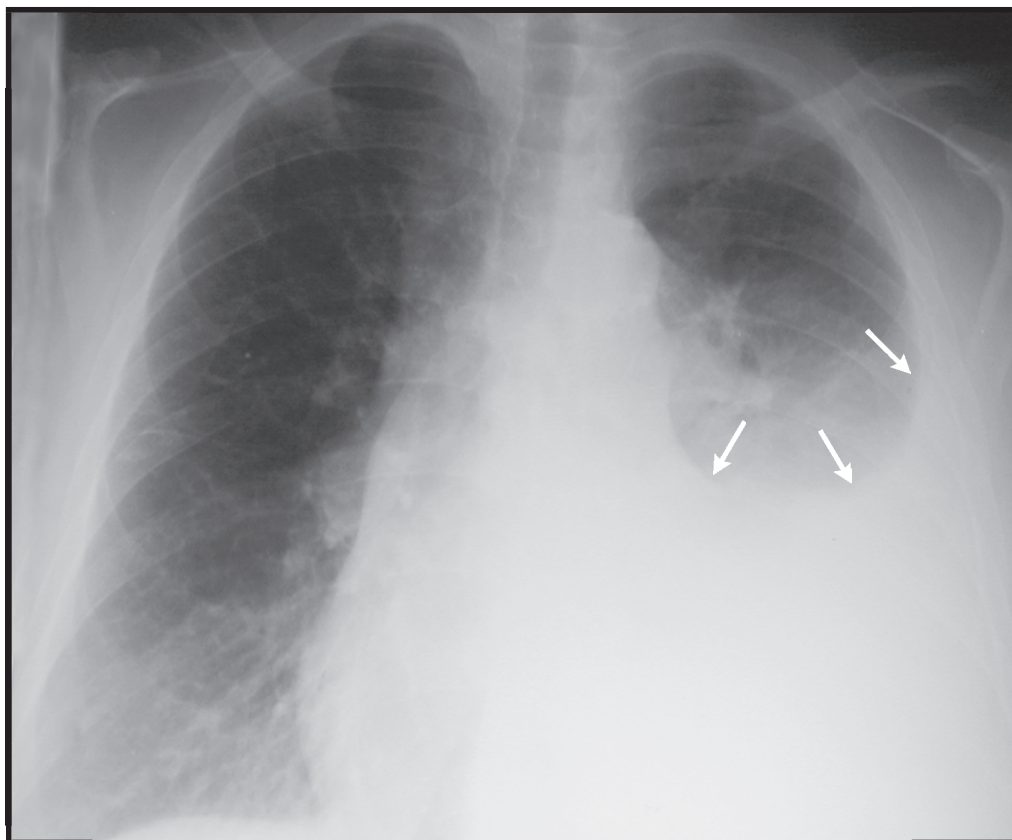
## ***Pleural Abnormalities***

The radiograph in *Figure 1.14* demonstrates extensive opacity in the lateral aspect of the right hemithorax, creating a very smooth, discrete interface with adjacent lung (arrows). This radiograph demonstrates:

- Large left pleural effusion
- Left lung consolidation

## ***Pleural Abnormalities***

***Figure 1.14: Pleural Effusion***



### ***Key Points***

- Because pleural abnormalities are, by definition, outside the lung parenchyma (extraparenchymal), an air bronchogram cannot be seen.
- Pleural abnormalities are usually homogeneous opacities.
- In the upright patient a pleural effusion will form a curvilinear interface with aerated lung that resembles a meniscus. This occurs because the pleural fluid settles dependently within the pleural space.
- In the supine patient, a pleural effusion may layer posteriorly in a dependent fashion, creating a hazy opacity over the entire involved hemithorax.
- When pleural effusions are loculated, they may appear nondependent. Focal pleural thickening or neoplasms involving the pleura may occasionally have a similar appearance.

### ***Diagnosis***

Large left pleural effusion (arrows delineate meniscus) secondary to congestive heart failure

## ***Cardiomediastinal Contour Abnormalities and Soft Tissue and Osseous Abnormalities***

---

Cardiomediastinal contour abnormalities are apparent on plain radiography because they cause unexpected interfaces with an adjacent lung. However, a discussion of cardiomediastinal abnormalities and soft tissue and bone abnormalities on chest radiography is beyond the scope of this primer. The interested reader is directed to several excellent references regarding chest radiograph interpretation listed at the end of this chapter.

## ***Self-Check Two***

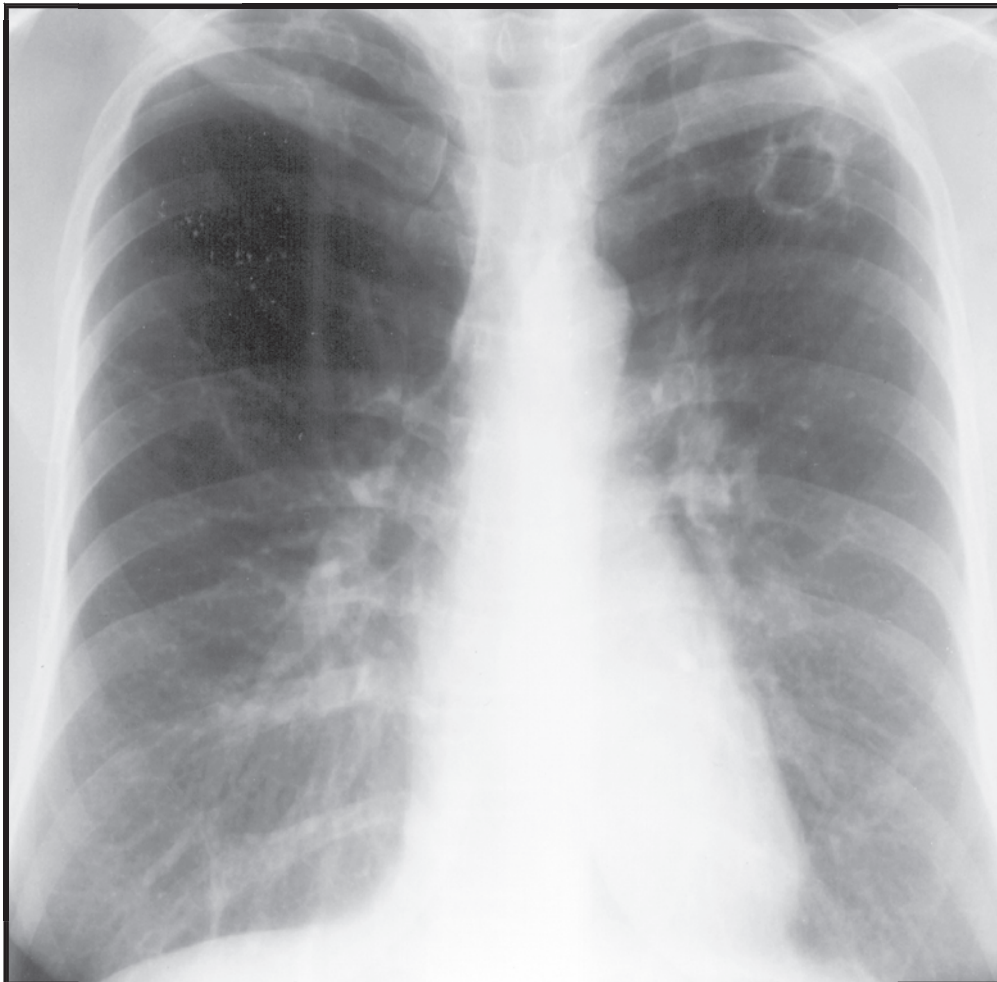The following self-check will help you assess your understanding of the previous material. Circle the best answer for each of the following statements.

After completing the self-check, look at the answers on page 1-52. Review the subjects in the previous pages to clarify any answers you have missed.

1. *Figure 1.15* demonstrates which of the following abnormalities?

- A.** Pulmonary nodule
- B.** Pulmonary mass
- C.** Lymphadenopathy
- D.** Cavity
- E.** Cardiomeastinal contour abnormalities

***Figure 1.15: Self-Check***



Circle the best answer for each of the following statement:.

2. Lymphadenopathy appears on the chest radiograph as soft tissue densities in characteristic locations such as:

- A.** Right paratracheal area
- B.** Aortopulmonary window
- C.** Paraspinous region
- D.** Subcarinal region
- E.** All of the above

3. Pulmonary nodules may be single or multiple and can manifest on the radiograph as:

- A.** Airspace opacities
- B.** Interstitial opacities
- C.** Focal lucent areas
- D. A and B**
- E. B and C**

4. Pulmonary cavities are created by necrosis of lung parenchyma resulting from:

- A.** Infection
- B.** Neoplasm
- C.** Infarction
- D.** All of the above
- E.** None of the above

## ***Self-Check Two (continued)***

Match the definitions with the terms in the right column. Write the letter of the term next to its correct definition. One of the terms is not defined.

☐

5. These become apparent on plain radiography because the abnormality causes an unexpected interface with an adjacent lung.

☐

6. Focal pulmonary parenchymal spaces that do not contain lung but are filled with either air or fluid or both.

☐

7. A fluid collection that creates a curvilinear interface with aerated lung that resembles a meniscus.

☐

8. Discrete opacity on a radiograph that is greater than 30 mm in diameter.

**A.** Pulmonary cysts

**B.** Reticulation

**C.** Pleural effusion

**D.** Cardiomedial contour abnormalities

**E.** Mass

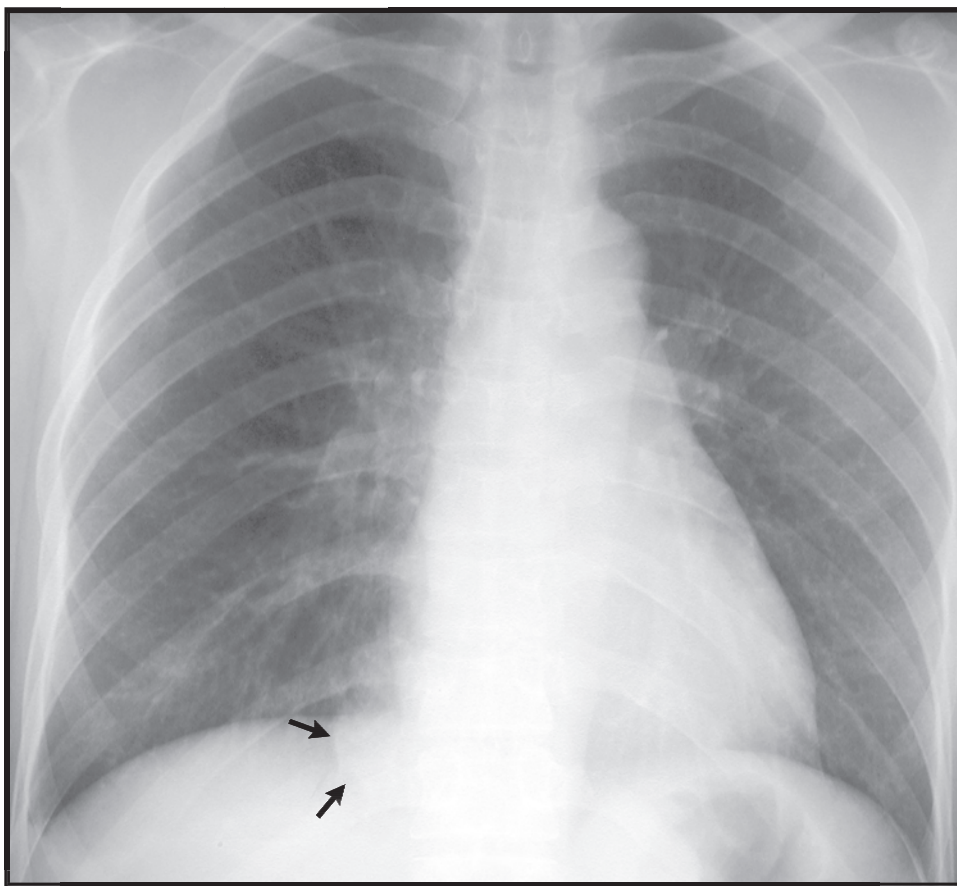


## ***A Final Word About Evaluating the Entire Radiograph***

Although it seems obvious to state that one must evaluate the entire radiograph, this point cannot be overemphasized. In particular, certain areas of the radiograph that are either difficult to examine or are often overlooked include:

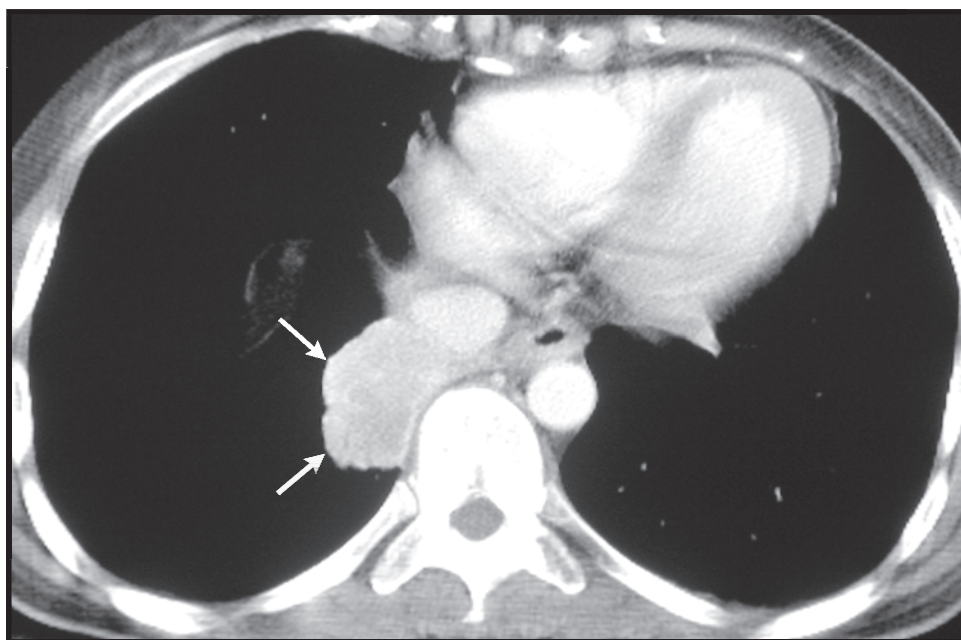
- the left and right retrocardiac areas (behind the heart)
- the apices
- the hilar regions
- and below the diaphragm.

***Figure 1.16: Right Lower Lobe Lung Carcinoma***



*Figure 1.16* demonstrates an unusual contour seen “through” the medial aspect of the right upper abdomen, just below the base of the right heart (arrows).

**Figure 1.17: CT Scan: Right Lower Lobe Lung Carcinoma**



CT scan of the chest (*Figure 1.17*) of the patient in *Figure 1.16* reveals an irregular mass in the medial aspect of the right lower lobe (arrows). This lesion was proven to represent carcinoma at biopsy. Note how the lesion lies posterior to the right heart; this position makes it somewhat difficult to detect with chest radiography.

You must use your knowledge of normal roentgen anatomy to actively “look through” the heart and diaphragm to evaluate the underlying pulmonary parenchyma. In the apices and hilar regions, you must mentally subtract the overlying bones and vascular structures to “see through” them to evaluate the underlying pulmonary parenchyma.

When required, apical lordotic views may provide better visualization of the lung apices. Frontal shallow oblique radiographs with 5–10° obliquity are occasionally useful to distinguish superimposed shadows that may create the appearance of a pulmonary nodule from a true pulmonary nodule.

### ***Distribution of Disease***

---

After an abnormality is identified, the distribution of the finding should be noted. Diseases affecting the pulmonary parenchyma are broadly characterized as having an upper, middle, or lower lung distribution. For example, upper lobe, predominantly small nodules and linear opacities, particularly with bilateral hilar lymphadenopathy, suggest the diagnosis of sarcoidosis. Characterization of a process as either central or peripheral may also evoke a specific differential diagnosis. Patchy migratory and peripheral consolidations, for example, are common manifestations of either eosinophilic pneumonia or organizing pneumonia. Finally, a disease process may be characterized as focal, multifocal, or diffuse. Proper characterization of disease distribution often allows the generation of a limited differential diagnosis.

## ***Conclusion***

A basic understanding of the physics underlying chest radiography is required to understand the power and limitations of plain radiography as well as to properly characterize pathology.

Furthermore, a working understanding of normal roentgen anatomy is necessary to distinguish normal tissue from abnormal tissue and to accurately localize disease processes.

To construct an ordered differential diagnosis, you must

- understand and use the proper terminology to characterize abnormalities identified on the chest radiograph
- and clearly note the distribution of the findings.

Carefully scrutinize the entire radiograph, paying special attention to particular areas of the radiograph that are often overlooked, to ensure that you do not miss significant abnormalities.

## ***References***

Austin JH, Muller NL, Friedman PJ, et al. Glossary of terms for CT of the lungs: recommendations of the Nomenclature Committee of the Fleischner Society. *Radiology*. 1996;200:327-331.

Fraser RA, Muller NL, Colman N, Pare PD. Diagnosis of Diseases of the Chest. In: Fraser RA, Muller NL, Colman N, Pare PD, eds. *Diagnosis of Diseases of the Chest*. Philadelphia, PA: WB Saunders; 1999:33-50, 77-104.

Tuddenham WJ, and the Nomenclature Committee of the Fleischner Society. Glossary of terms for thoracic radiology: recommendations of the Nomenclature Committee of the Fleischner Society. *Am J Roentgenol*. 1984;143:509-517.

**CHAPTER TWO**

# ***Radiographic Manifestations of Tuberculosis***

## ***Introduction***

In Chapter One, we learned the basic principles of chest radiography and how to read and interpret a chest radiograph using standard terminology.

In Chapter Two, we review the radiographic manifestations of pulmonary tuberculosis and use the terminology we learned in the previous chapter to describe the radiographic findings. By the end of this chapter, you will be familiar with the various radiographic manifestations of tuberculosis.

Let's begin with an overview of the pathogenesis of tuberculosis to better understand the radiographic manifestations that you will encounter in your practice.

## ***Overview of the Pathogenesis of Tuberculosis***

When tubercle bacilli are inhaled into the lung, the bacilli are deposited in the airways and alveoli in more ventilated areas of the lung—typically in the middle to lower regions. The initial inflammatory reaction in the lung is referred to as a **primary** or **Ghon focus**.

During this early stage of infection, organisms can spread via lymphatics to the draining lymph nodes in the chest and result in enlargement of hilar and mediastinal lymph nodes. Bacilli can also enter the blood stream where they spread hematogenously throughout the body. Disease presenting at this stage is referred to as **primary** tuberculosis and is associated with certain radiographic findings, which we will review shortly.

After several weeks, the host develops cell-mediated immunity and delayed-type hypersensitivity that, in most cases, result in control of the infection. However, the healed lesions often contain viable bacilli that can progress to disease in the future. Such progression causes **post-primary** or **reactivation** tuberculosis. Post-primary disease is also associated with certain radiographic findings related to the fact that the host has now developed cell-mediated immunity and delayed-type hypersensitivity. It is not surprising that this entire pathogenetic sequence represents a continuum and many of the radiographic manifestations of primary and post-primary tuberculosis overlap.

The pathogenetic sequence described above becomes even less distinct in patients with underlying human immunodeficiency virus (HIV) infection. The radiographic presentation of tuberculosis in HIV-infected patients includes both primary and post-primary disease. In patients with advanced HIV disease, post-primary disease may present radiographically as primary tuberculosis.

This chapter reviews the radiographic manifestations of tuberculosis by dividing them into two categories:

- Primary disease
- Post-primary disease

It is important to point out that the distinction between primary and post-primary tuberculosis has little clinical relevance. Active tuberculosis disease should be treated regardless of whether it is primary or post-primary in nature. Patients who are suspected of having tuberculosis should be evaluated for disease regardless of the appearance of the chest radiograph.

## ***Primary Tuberculosis***

Primary tuberculosis occurs soon after infection with *M. tuberculosis*, in some instances before cell-mediated immunity and delayed-type hypersensitivity have developed.

After inhalation of the tubercle bacillus, an early inflammatory response develops at the site of infection that is referred to as the primary focus or Ghon focus. The Ghon focus may be visualized on the chest radiograph as an airspace opacity and is commonly associated with a radiographically evident enlargement of the ipsilateral hilar or paratracheal lymph nodes. The combination of the Ghon focus and ipsilateral lymphadenopathy is called the **primary complex** or **Ranke complex**.

In order to review the radiographic manifestations of primary tuberculosis we will divide the findings into the following categories:

- Distribution of parenchymal disease
- Patterns of disease
- Tracheobronchial disease
- Hilar and mediastinal lymphadenopathy
- Pleural disease

### ***Distribution of Parenchymal Disease***

---

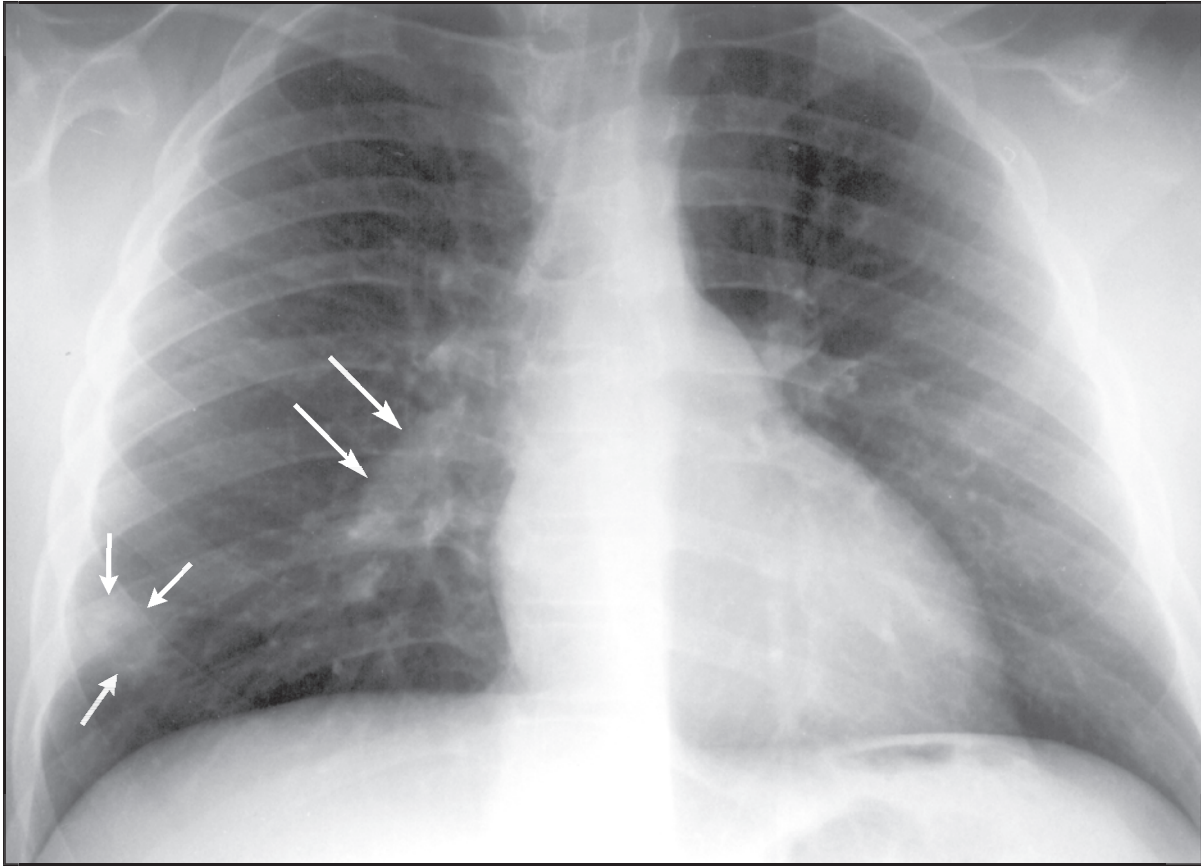
Although primary tuberculosis can affect any segment of the lung parenchyma, the lower lobes are characteristically involved more often in primary tuberculosis than in post-primary disease. However, this predilection varies with age. In children, it appears that the upper and lower lobes are involved with equal frequency, whereas in adults, there is a slight predilection for lower lobe involvement.

The following are examples of the parenchymal distribution of primary tuberculosis in children and adults.



## Primary Tuberculosis in a Child

**Figure 2.1: Primary Tuberculosis in a Child**



*Figure 2.1* demonstrates a peripheral airspace opacity (small arrows) in the right lower lobe and right hilar lymphadenopathy (large arrows). This is an example of the primary complex (Ghon focus and ipsilateral hilar lymphadenopathy) that is typical of primary tuberculosis in a child.

**Figure 2.2: Primary Tuberculosis in a Child**

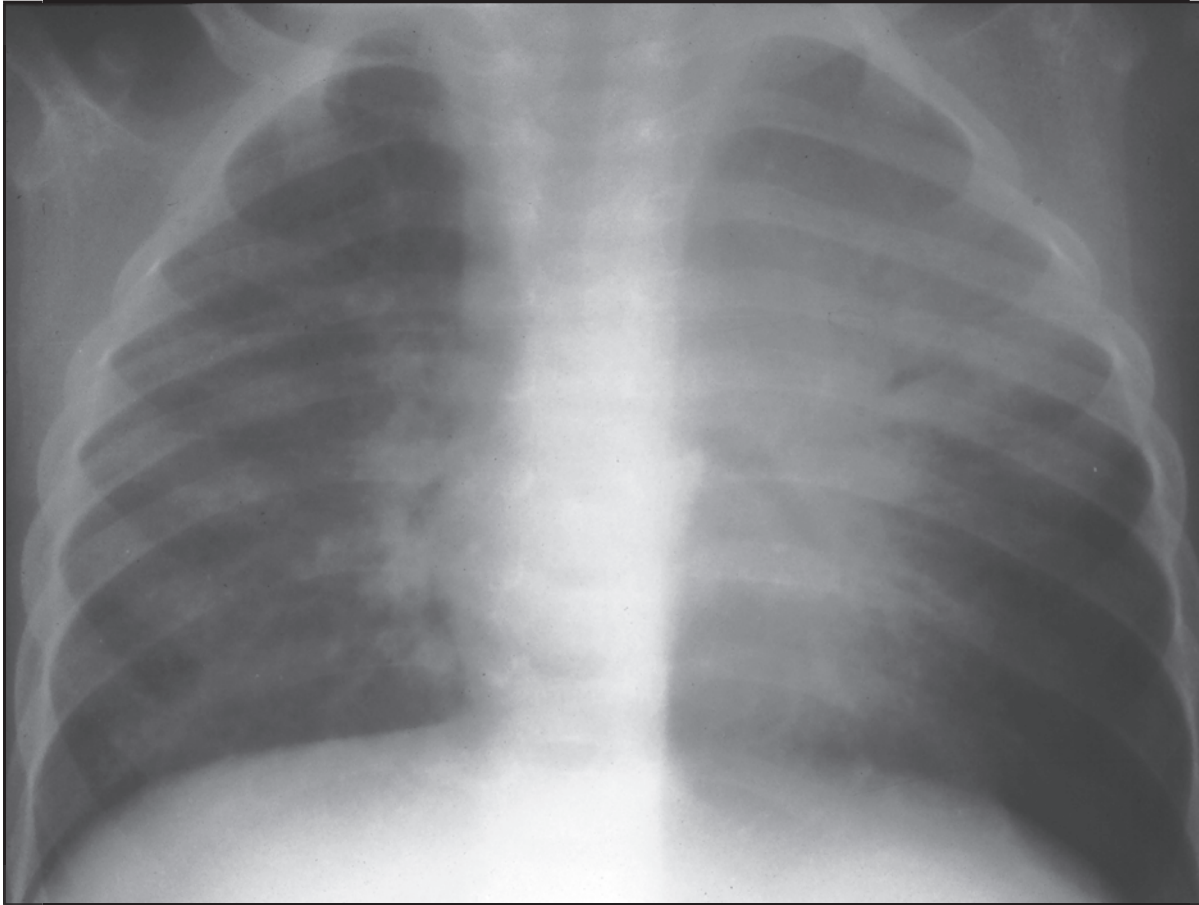
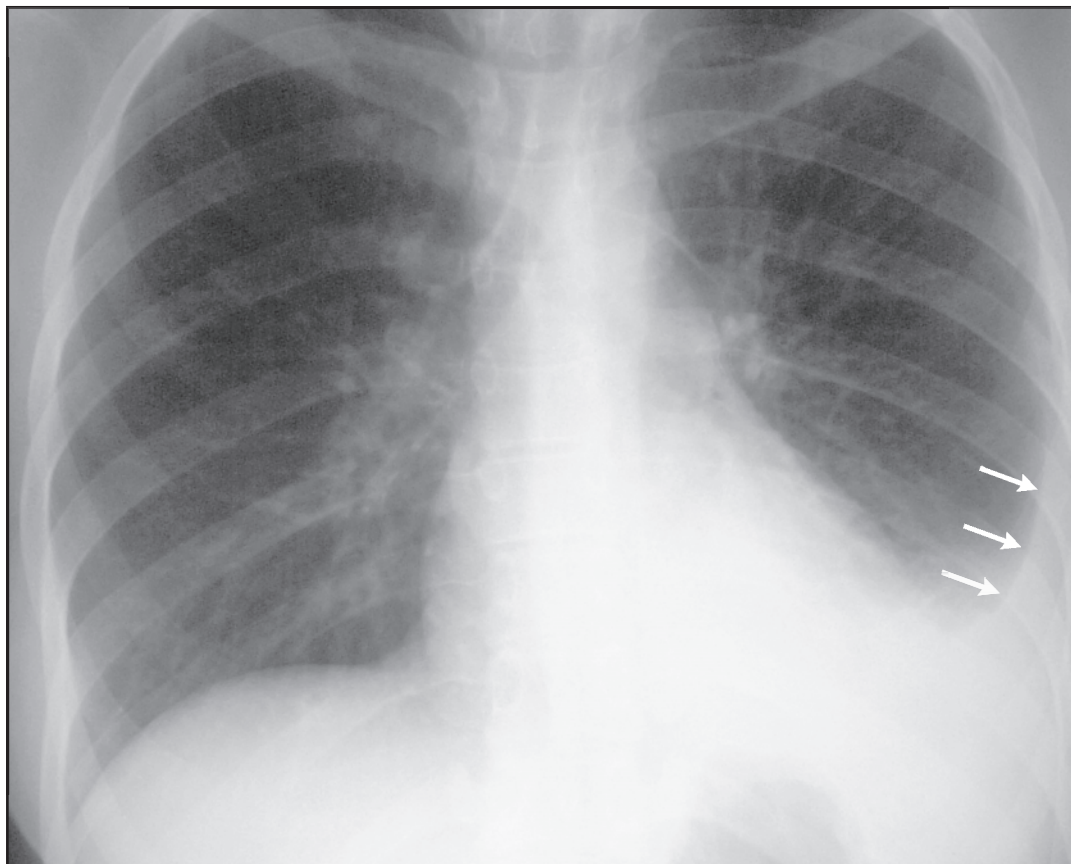


Figure 2.2 demonstrates a left upper lobe airspace opacity in a 4-year-old child with tuberculosis. Note the silhouette sign (absence of a distinct left heart border).

- The upper and lower lobes are affected equally in children.
- Radiographically, the primary complex consists of a parenchymal opacity and enlargement of ipsilateral thoracic lymph nodes.
- Involvement of the anterior segment of the upper lobes can occur in primary disease but is uncommon in reactivation disease in adults.
- There is a slight predilection for right-sided involvement.

## Primary Tuberculosis in an Adult

*Figure 2.3: Primary Tuberculosis in an Adult*



*Figure 2.3* demonstrates a left lower lobe airspace opacity and a homogeneous opacity extending up the left lateral chest wall (arrows). These findings are consistent with consolidation and a pleural effusion, which are characteristic of primary tuberculosis in an adult. Note that the left hemidiaphragm is not visible (silhouette sign).

- The lower lobes are affected more often in adults with primary disease than the upper lobes.
- Anterior segment involvement can occur, which is unusual in post-primary disease.
- Cavitation, though unusual, can occur in adults with progressive primary tuberculosis.

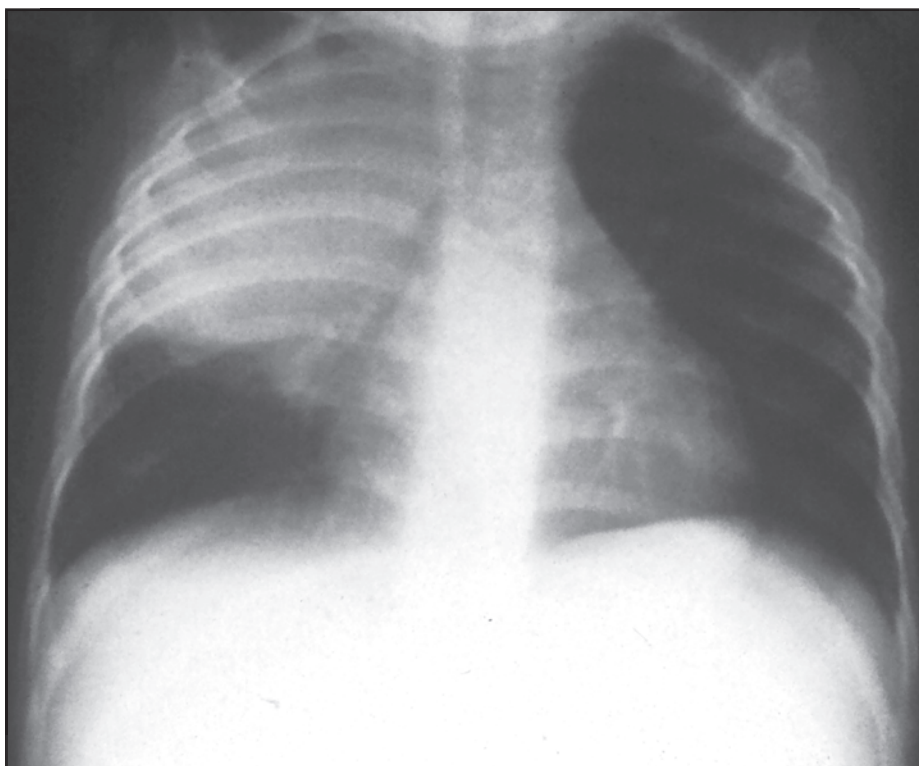
## ***Patterns of Disease***

---

In the setting of primary tuberculosis, parenchymal opacities may be airspace or interstitial in nature. Airspace consolidation is the most common radiographic pattern in primary disease. The most common interstitial pattern of primary disease is that of miliary (or disseminated) tuberculosis. Other primary manifestations of tuberculosis include tracheobronchial disease, hilar and mediastinal lymphadenopathy and pleural disease.

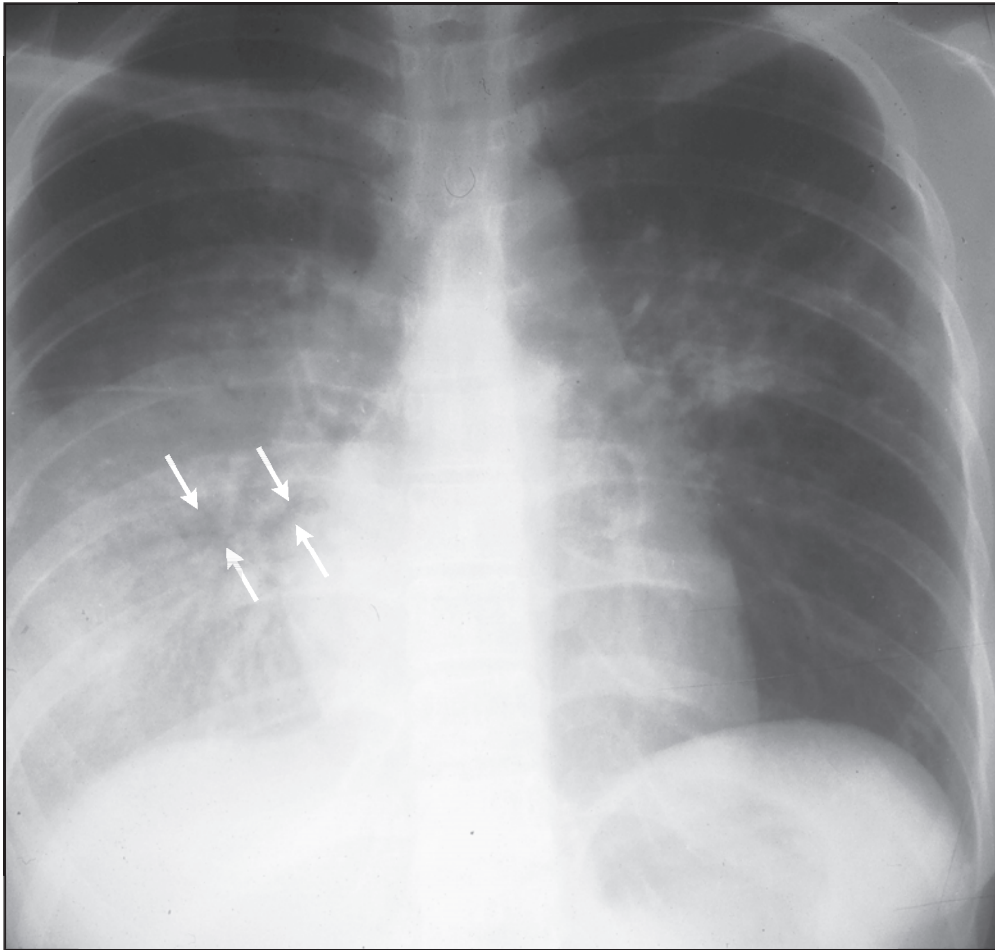
### **Airspace Consolidation**

***Figure 2.4: Primary Tuberculosis in a Child with Airspace Consolidation***



*Figure 2.4* demonstrates a right upper lobe consolidation and right hilar adenopathy in a young child. Note the absence of aerated lung in the right upper lobe.

**Figure 2.5: Primary Tuberculosis in a Young Adult with Airspace Consolidation**



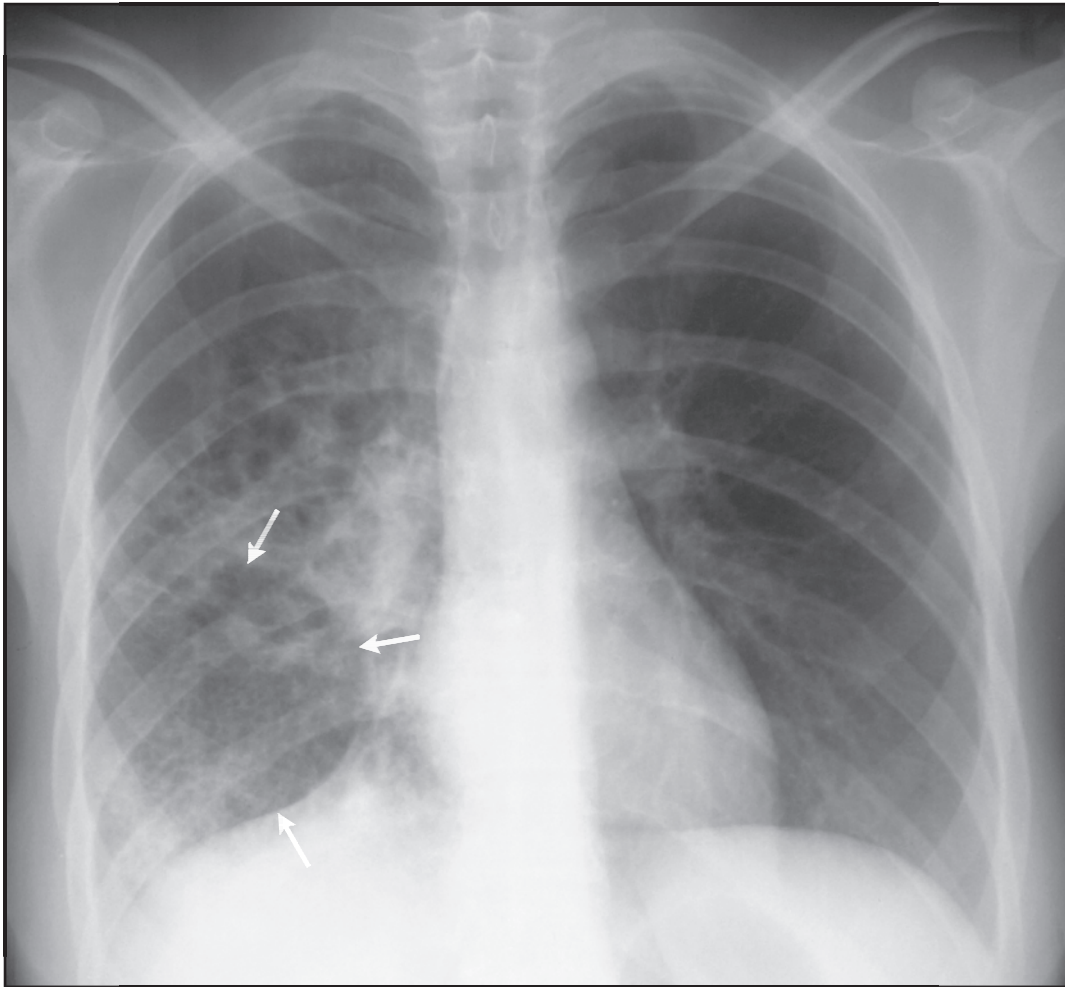
*Figure 2.5* demonstrates right lower lobe airspace consolidation with air bronchograms (arrows) and left mid-lung airspace opacities. Note the difficulty in seeing the right hemidiaphragm because consolidated lung is adjacent to the tissue density of the diaphragm (silhouette sign). The patient was a young college student with primary tuberculosis.

- Airspace consolidation is the typical appearance of primary disease in an adult.
- The consolidation is usually homogeneous in density.
- Air bronchograms may be visualized in the area of consolidation.
- Cavitation is unusual.



## Airspace Consolidation with Cavitation

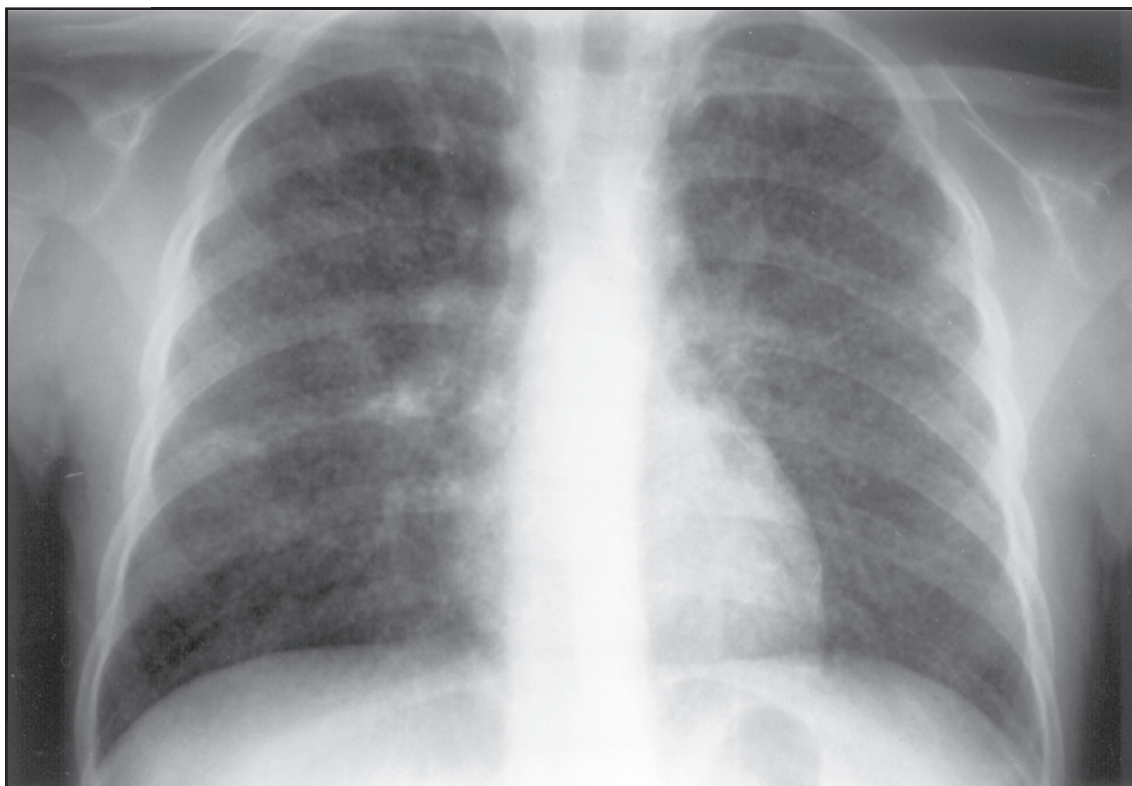
**Figure 2.6: Primary Tuberculosis with Cavitation**



*Figure 2.6* demonstrates right lower and middle lobe airspace consolidation with multiple cystic areas (pneumatoceles) and cavities. The patient was a 29-year-old woman who developed tuberculosis soon after exposure to a homeless man with tuberculosis. Note the large cystic area (arrows) that was confirmed by CT scan.

- Cavitation is relatively uncommon in primary disease, particularly in young children.
- Cavitation can occur with progressive primary disease.
- Pneumatocele formation is uncommon but can develop in the setting of progressive primary disease.



**Interstitial Pattern (Miliary)*****Figure 2.7: Miliary Pattern***

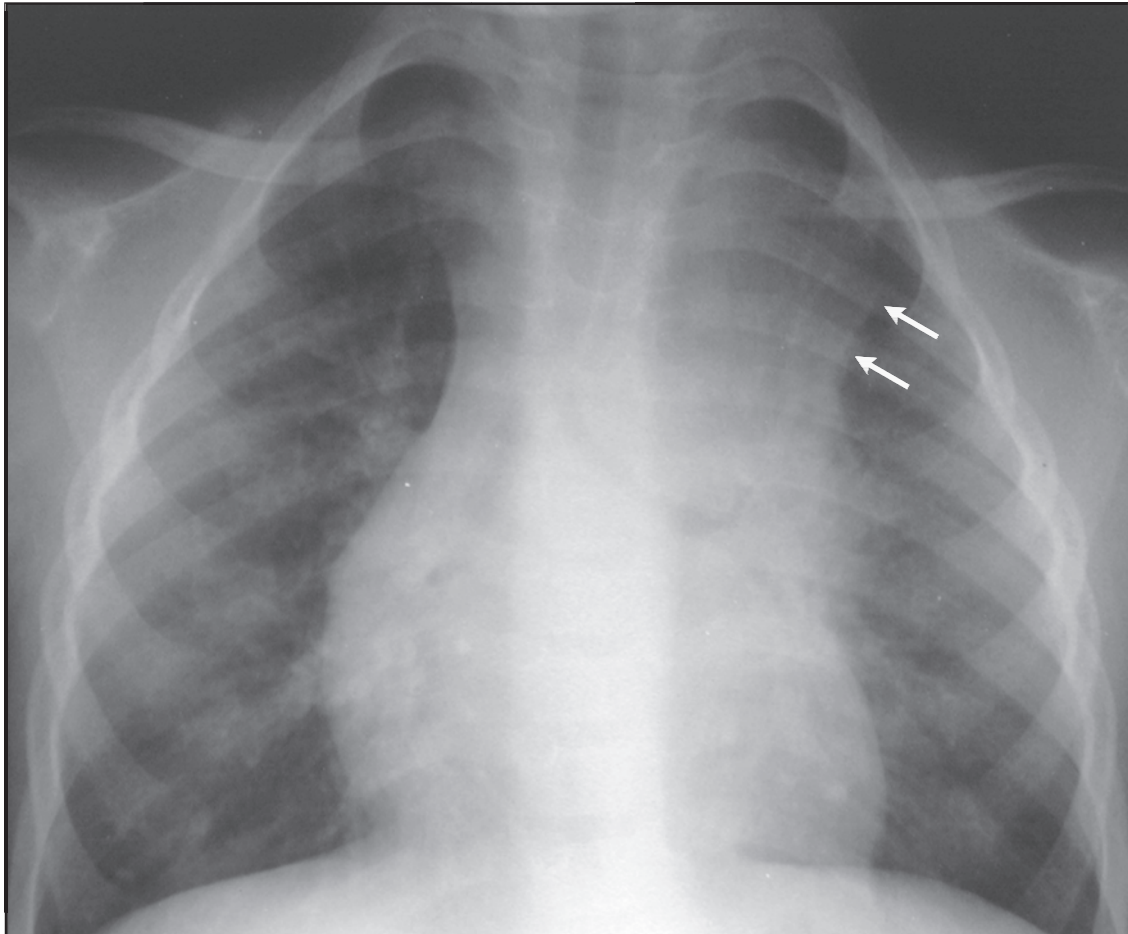
*Figure 2.7* demonstrates bilateral diffuse small nodules (2–3 mm in diameter) consistent with a miliary pattern. The patient was a 5-year-old girl with disseminated tuberculosis.

- Miliary disease can occur as a consequence of primary or post-primary disease.
- A miliary pattern results from hematogenous dissemination of tubercle bacilli that leads to many nodules of variable size, initially present in the interstitium and ultimately involving the airspaces.
- Most of the nodules in miliary tuberculosis are 2 mm in diameter.
- Because miliary nodules result from hematogenous dissemination, more are usually present in the lower lung zones because of greater blood flow to the bases compared with the apices of the lungs.

## Tracheobronchial Disease

Volume loss (atelectasis) can be caused by fibrotic scarring, endobronchial obstruction, or extrinsic compression of airways by enlarged lymph nodes. Extrinsic compression of airways is particularly common in children because they have compressible airways. In primary tuberculosis, endobronchial lesions and extrinsic compression by enlarged lymph nodes are the most common reasons for volume loss.

**Figure 2.8: Airspace Consolidation with Atelectasis**



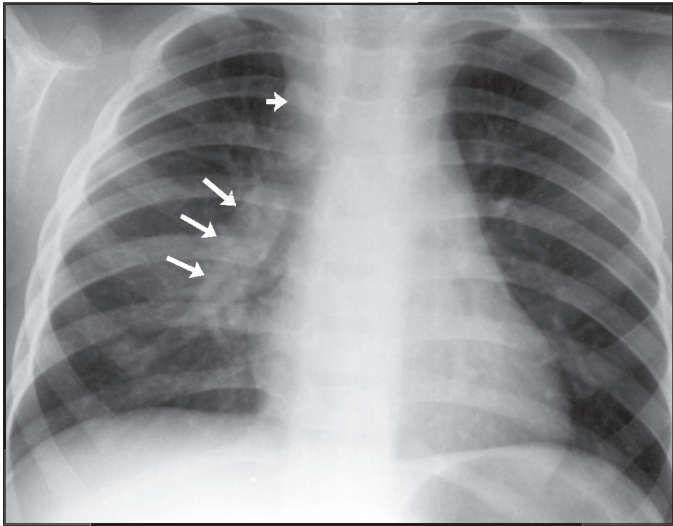
*Figure 2.8* demonstrates left upper lobe airspace opacification with atelectasis. The inferior margin of the airspace consolidation is straight and well visualized (arrows) against the air-containing lower lobe. This represents the major fissure separating the upper and lower lobes.

- Atelectasis caused by tuberculosis may result from obstruction of an airway from endobronchial disease or from extrinsic compression due to enlarged lymph nodes.
- The anterior segment of the upper lobe or the medial segment of the middle lobe are most often involved.
- Although less common in adults, segmental collapse is most likely to affect the anterior segment of the upper lobes.

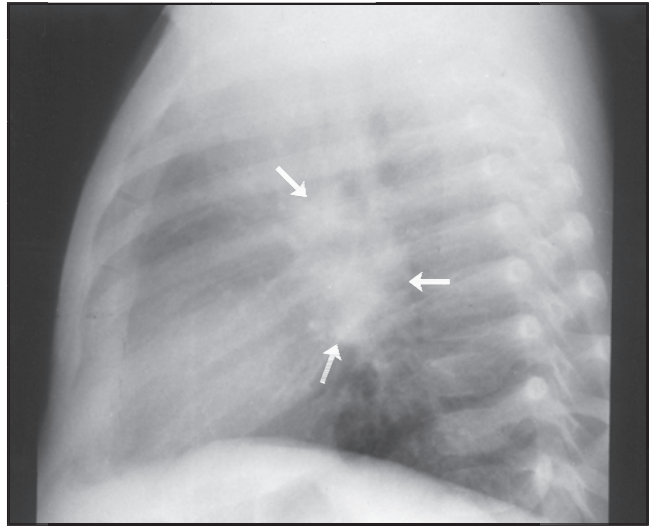
## Hilar and Mediastinal Lymphadenopathy

Early in the pathogenesis of tuberculosis, tubercle bacilli spread via lymphatics to draining lymph nodes in the hilar areas and mediastinum. Enlargement of these lymph nodes can sometimes be visualized on the chest radiograph. Adenopathy is particularly common in children with primary tuberculosis and adults with HIV infection.

**Figure 2.9a: Lymphadenopathy**



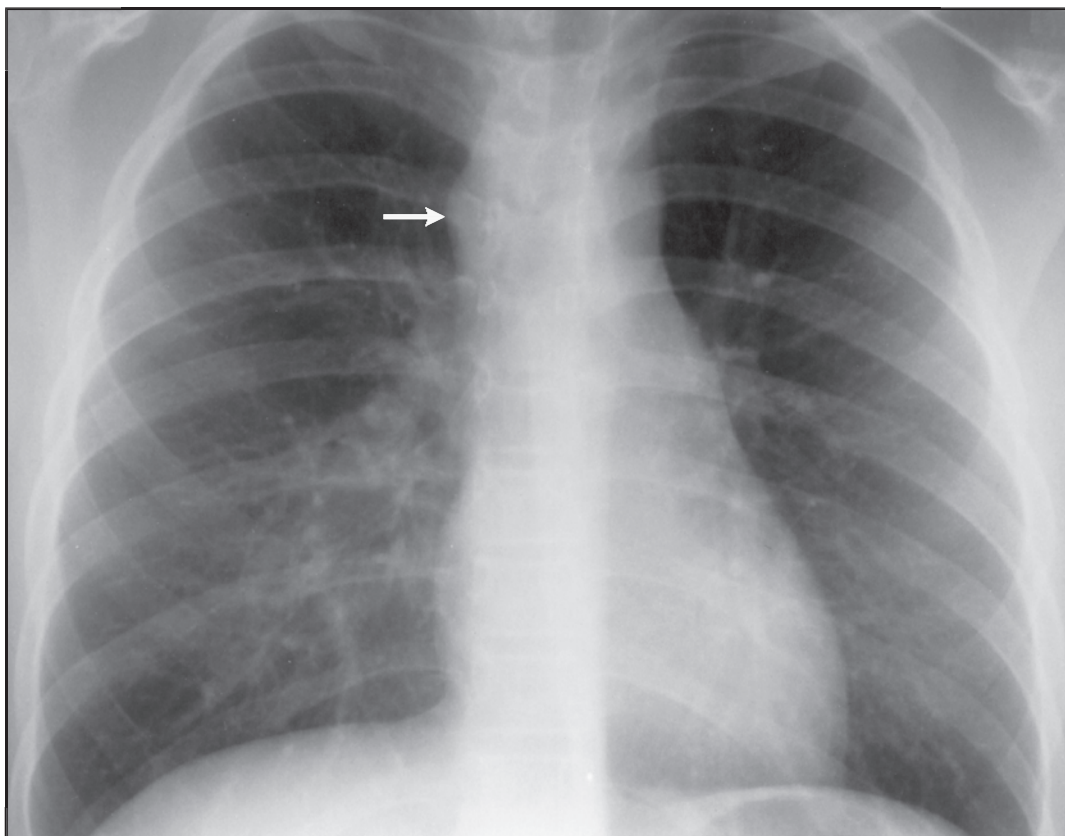
**Figure 2.9b: Lymphadenopathy**



*Figure 2.9a*, a radiograph of a 4-year-old child, demonstrates right hilar (large arrows) and paratracheal (smaller arrow) lymphadenopathy. The lateral radiograph, *Figure 2.9b*, also demonstrates hilar adenopathy (arrows).

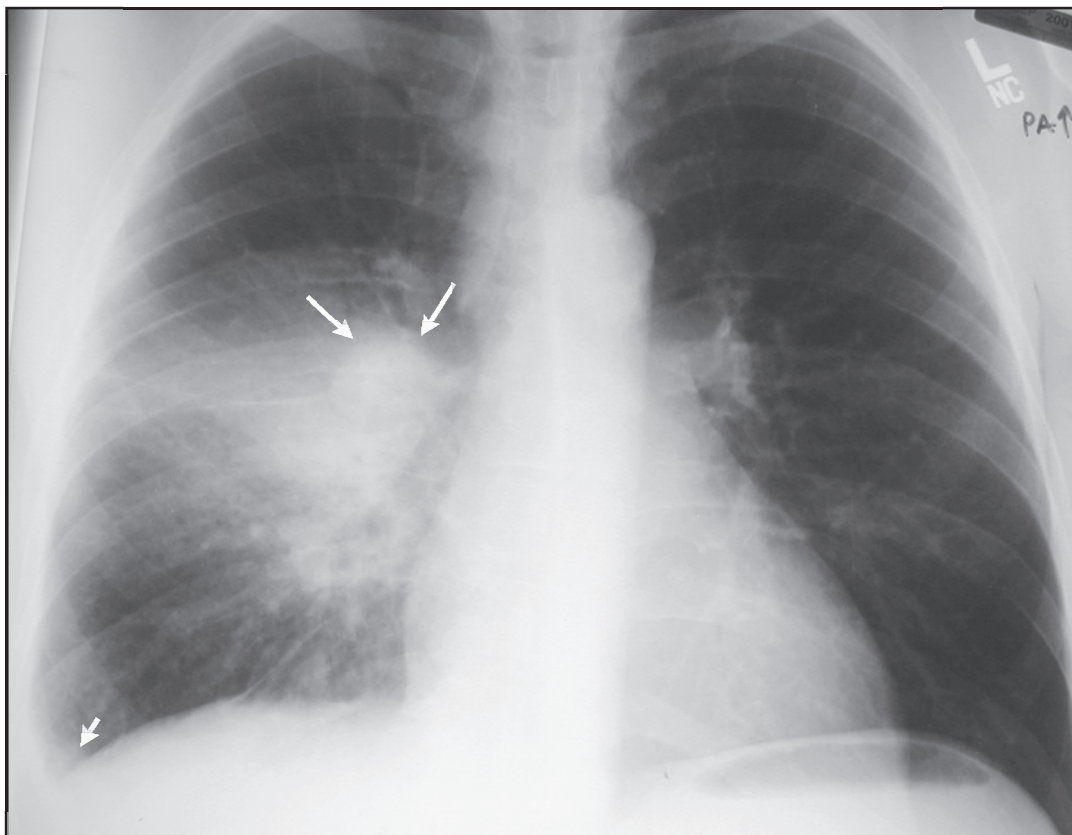
- Adenopathy is common among children and persons with HIV infection.
- There is a predilection for the right side, especially in the paratracheal and hilar areas.
- The younger the child, the more commonly adenopathy is present and the more often it is seen without parenchymal disease.
- Enlarged lymph nodes may cause compression of airways leading to atelectasis.
- A lateral chest radiograph is often necessary to confirm the presence of hilar adenopathy in young children.

**Figure 2.10: Lymphadenopathy**



*Figure 2.10*, a radiograph of a 10-year-old child with tuberculosis, shows thickening of the right paratracheal stripe (arrow) due to adenopathy.

**Figure 2.11: Lymphadenopathy**



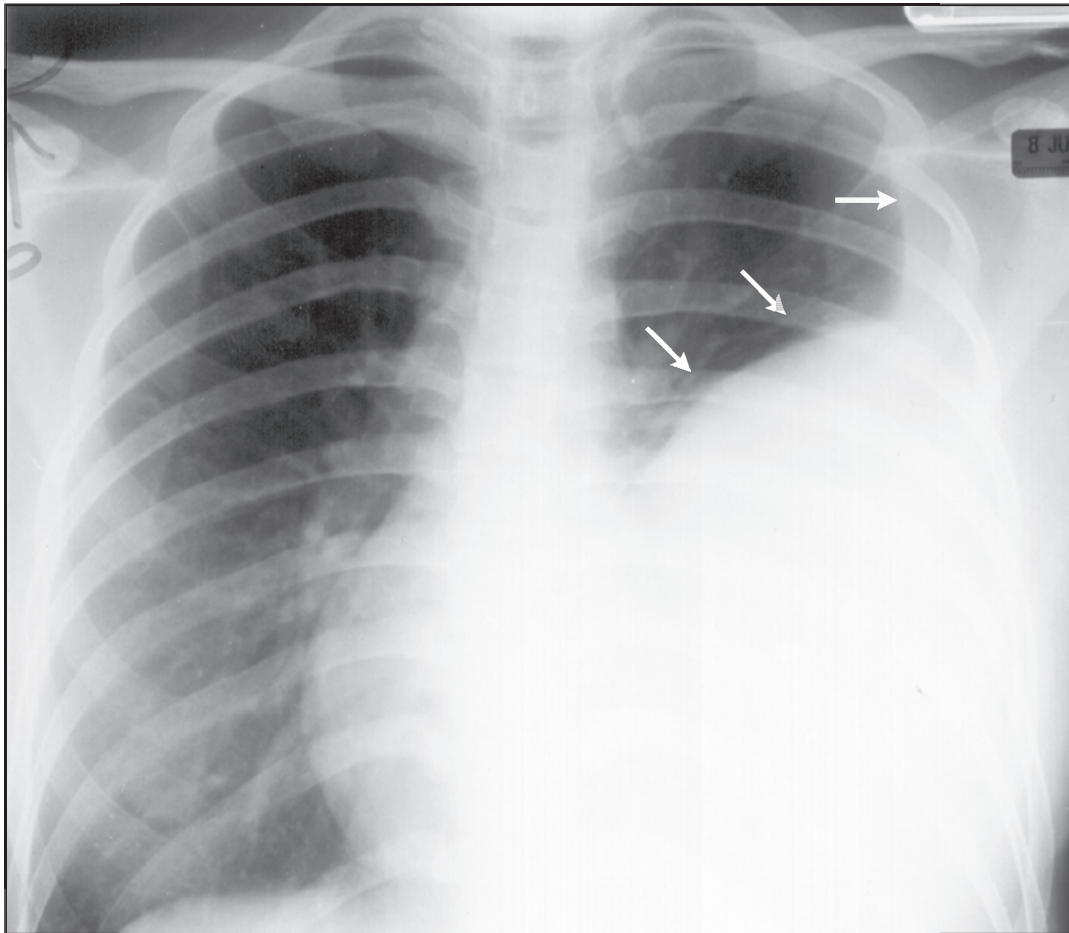
*Figure 2.11* is notable for probable right hilar adenopathy (large arrows), right mid-lung airspace opacity, and blunting of the right costophrenic angle (small arrow) consistent with a small pleural effusion. This HIV-negative patient had culture-confirmed primary tuberculosis.



## Pleural Disease

Pleural effusions that develop in the setting of primary disease are usually due to a delayed-type hypersensitivity reaction. These effusions can vary in size from small to large, sometimes occupying an entire hemithorax. In many cases, no parenchymal abnormality can be visualized on plain radiographs although CT scans and autopsy studies have documented underlying parenchymal disease in most cases. Recognition of a pleural effusion is important so that pleural fluid can be aspirated for diagnostic studies.

**Figure 2.12: Pleural Effusion**



*Figure 2.12* demonstrates a large left-sided pleural effusion (arrows). Note that the diaphragmatic border cannot be seen because the pleural liquid is adjacent to the diaphragm (silhouette sign).

- Pleural effusions are uncommon in children (10%).
- Pleural effusions are very common in adults with primary tuberculosis (40%).
- Pleural effusions may represent the only manifestation of primary tuberculosis, particularly in adolescents and young adults.
- Pleural effusions are usually unilateral and may vary in size.



This page left intentionally blank.

## ***Post-primary (Reactivation) Tuberculosis***

Post-primary tuberculosis is the most common form of disease in adults and occurs in individuals who have developed cell-mediated immunity and delayed-type hypersensitivity to *M. tuberculosis*. In most individuals with latent tuberculous infection, the immune system is able to control the infection. In some individuals however, the organism is able to reactivate and proliferate, leading to post-primary tuberculosis.

Although the radiographic manifestations of post-primary tuberculosis overlap with those of primary disease, there are several distinguishing features:

- Predilection for upper lobes
- Lack of lymphadenopathy
- Propensity for cavitation

Cavitation is an important characteristic of post-primary tuberculosis. In tuberculosis, cavities occur as the result of caseous necrosis and usually contain the highest concentration of mycobacteria of any tuberculous lesion. Hilar and mediastinal adenopathy will not be discussed here because they are unusual in the setting of post-primary tuberculosis. As with our previous discussion of primary disease, we will examine the radiographic manifestations of post-primary tuberculosis using the following categories:

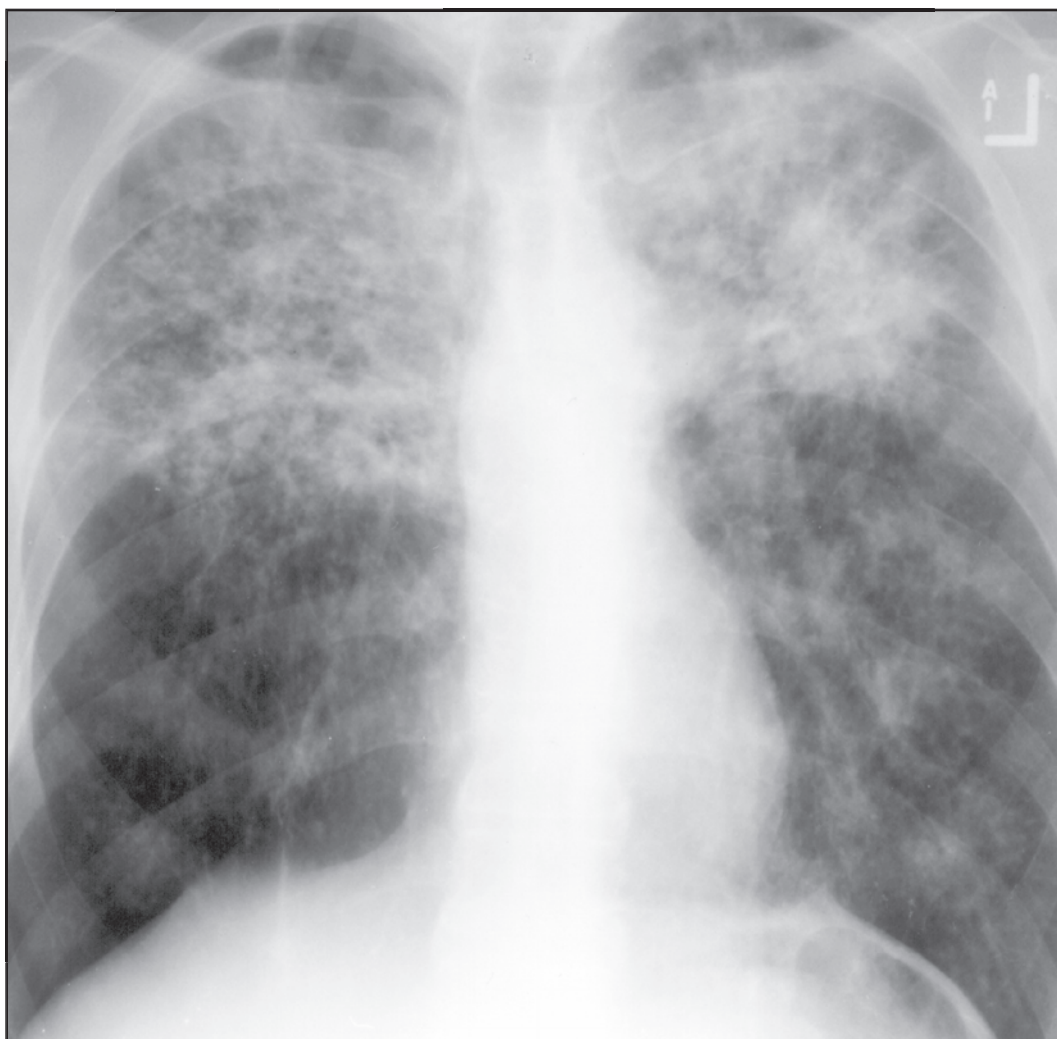
- Distribution of parenchymal disease
- Patterns of disease

## ***Distribution of Parenchymal Disease***

---

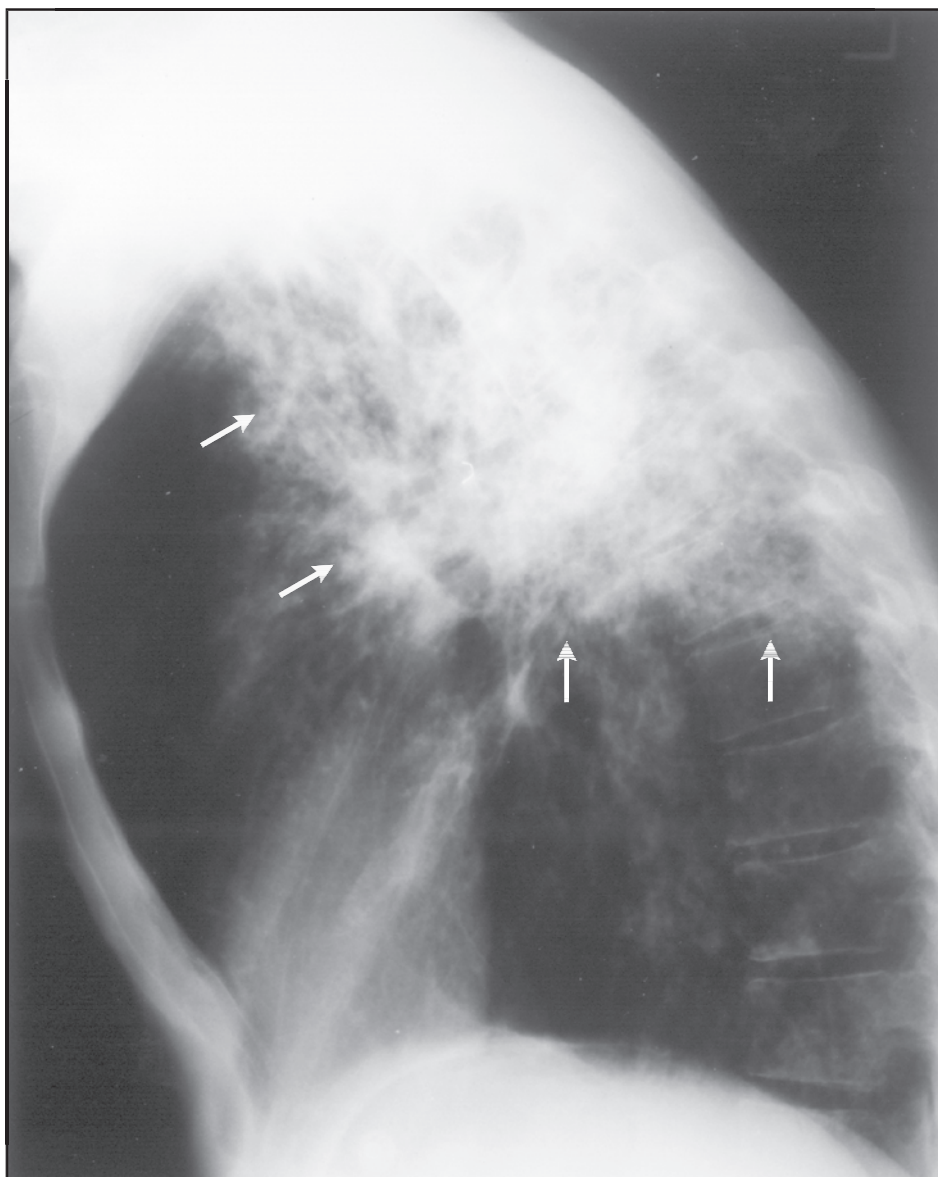
As with primary tuberculosis, any lung segment can be involved with tuberculosis. However, post-primary tuberculosis typically involves apical and posterior segments of the upper lobe. If the lower lobe is involved, the superior segment is the most common site of disease. Isolated anterior segment involvement, without other segmental disease, is very unusual in post-primary tuberculosis. The predilection for the upper lobes is thought to be due to decreased lymph flow in the upper regions of the lung. Historically, an alternative explanation is the presence of higher oxygen tension in that region.

***Figure 2.13a: Post-primary Tuberculosis***



*Figure 2.13a* demonstrates bilateral upper lobe apicoposterior segment consolidation characteristic of post-primary tuberculosis. Note the superior retraction of the hilar structures denoting volume loss.

**Figure 2.13b: Post-primary Tuberculosis, Lateral View**



In *Figure 2.13b*, a lateral view of the same patient in *Figure 2.13a*, the typical location of the apicoposterior segment is outlined by arrows.

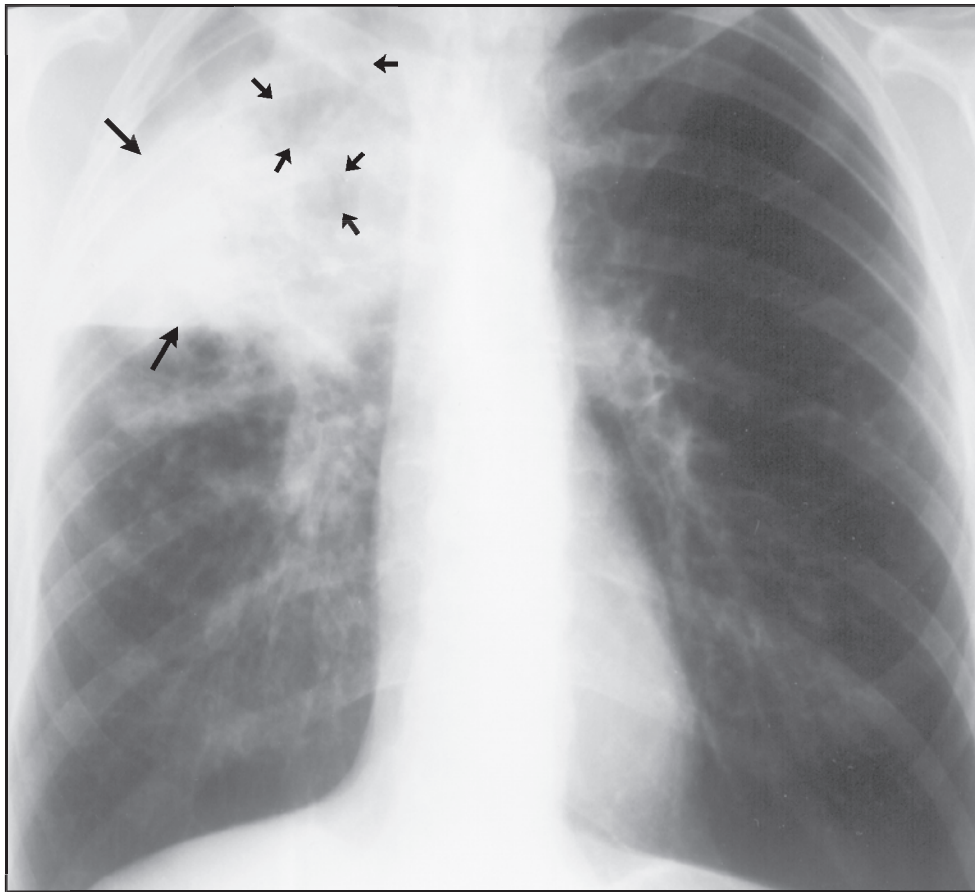
- Post-primary tuberculosis characteristically involves the apical and posterior segments of the upper lobes or the superior segment of the lower lobes.
- Decreased lymph flow in the upper regions of the lung is thought to be the cause of the predilection for the upper lobes.
- This upper lobe apical and posterior distribution is so typical that involvement of the anterior segment of the upper lobe without apical or posterior infiltrates makes the diagnosis of post-primary tuberculosis very unlikely.
- In most cases, more than one pulmonary segment is involved.

## ***Patterns of Disease***

Airspace consolidation is the most common pattern of disease, as in primary tuberculosis. In most cases, however, there is a mixture of radiographic patterns. For example, a mixture of linear, reticular, and nodular opacities is often called “fibronodular” or “fibroproductive.” Although these terms have fallen out of favor with radiologists, you are likely to see them used by clinicians. **It is important to keep in mind that disease activity cannot be determined based on the pattern of parenchymal involvement.**

### **Airspace Consolidation**

***Figure 2.14: Extensive Airspace Consolidation with Cavitation***



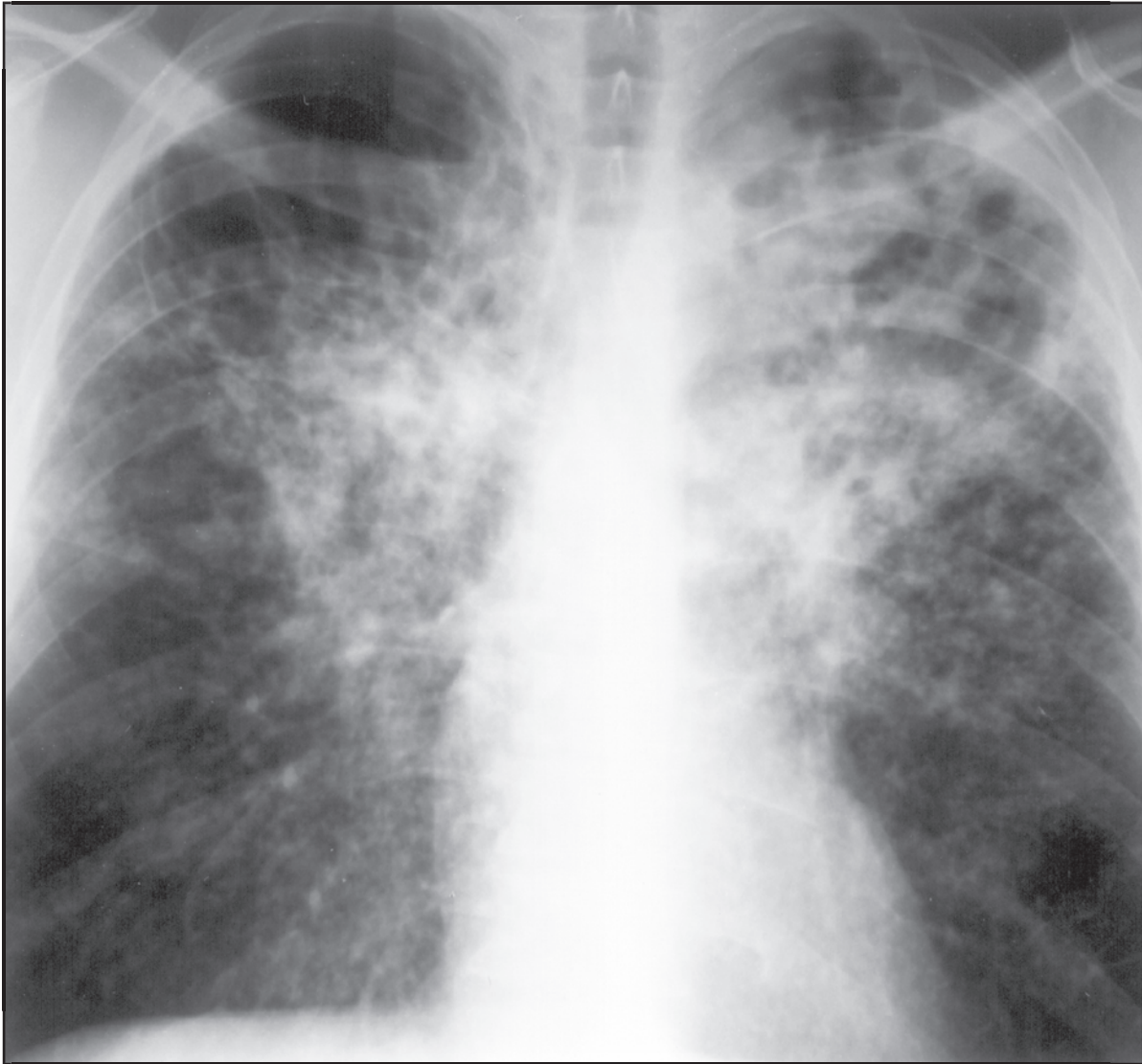*Figure 2.14* demonstrates extensive airspace consolidation (large arrows) in the right upper lobe with areas of cavitation (small arrows).

- Airspace consolidation is the most common parenchymal pattern in post-primary disease.
- Consolidation may be patchy or confluent.
- Air bronchograms may be present within the area of consolidation.
- Cavitation is commonly seen within the consolidated lung.



## Airspace Consolidation With Cavitation

***Figure 2.15: Airspace Consolidation with Cavitation***



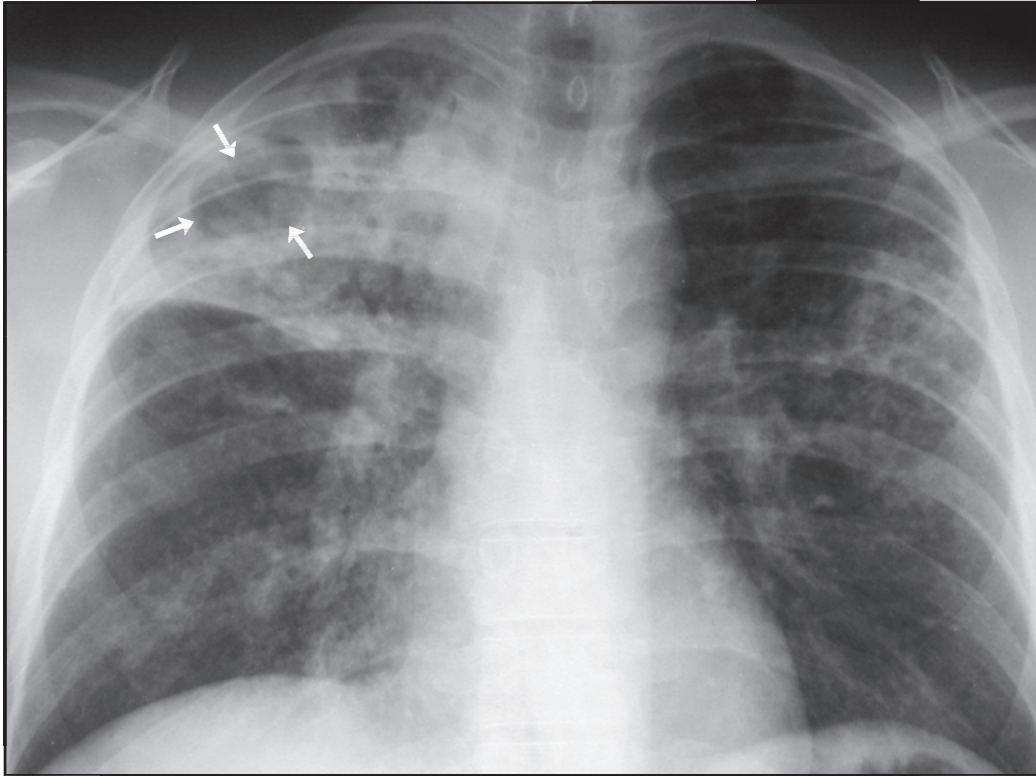
*Figure 2.15* demonstrates bilateral airspace consolidation with multiple areas of cavitation.

- Important radiographic features of cavities include the thickness of the cavity wall (walls of cavities are thicker than those of cysts), the presence of fluid, and whether lesions are solitary or multiple.
- In tuberculosis, cavities are the result of caseous necrosis and usually contain the highest concentrations of mycobacteria of any tuberculous lesion.
- Cavitation on chest radiographs is present in more than half of post-primary cases.
- Air-fluid levels within the cavity are uncommon but do occur.



## Airspace Consolidation with Bronchogenic Spread

**Figure 2.16: Airspace Consolidation with Bronchogenic Spread**



*Figure 2.16* demonstrates bilateral (right>left) upper lobe airspace consolidation. There is a large cavity in the right upper lobe (arrows). Note the nodular airspace opacities in the left upper lobe and right middle lobe that represent bronchogenic spread of tuberculosis from the right upper lobe.

- In tuberculosis, bronchogenic spread results from the communication of infectious material within the bronchial tree, leading to new foci of infection in other bronchopulmonary segments, manifested as airspace nodules.
- Airspace nodules are 4 to 10 mm in diameter. They have poorly defined borders and multiple small radiolucencies within their confines caused by air within bronchioles and alveoli.
- These nodules are best seen with high-resolution CT.

## Airspace Consolidation with Volume Loss

Volume loss (atelectasis) can be caused by fibrotic scarring, endobronchial obstruction, or extrinsic compression of airways by enlarged lymph nodes. In the setting of post-primary tuberculosis, volume loss is usually due to fibrosis. In some cases, fibrosis leads to narrowing of an airway (bronchostenosis), which can result in segmental or lobar collapse.

**Figure 2.17: Atelectasis**

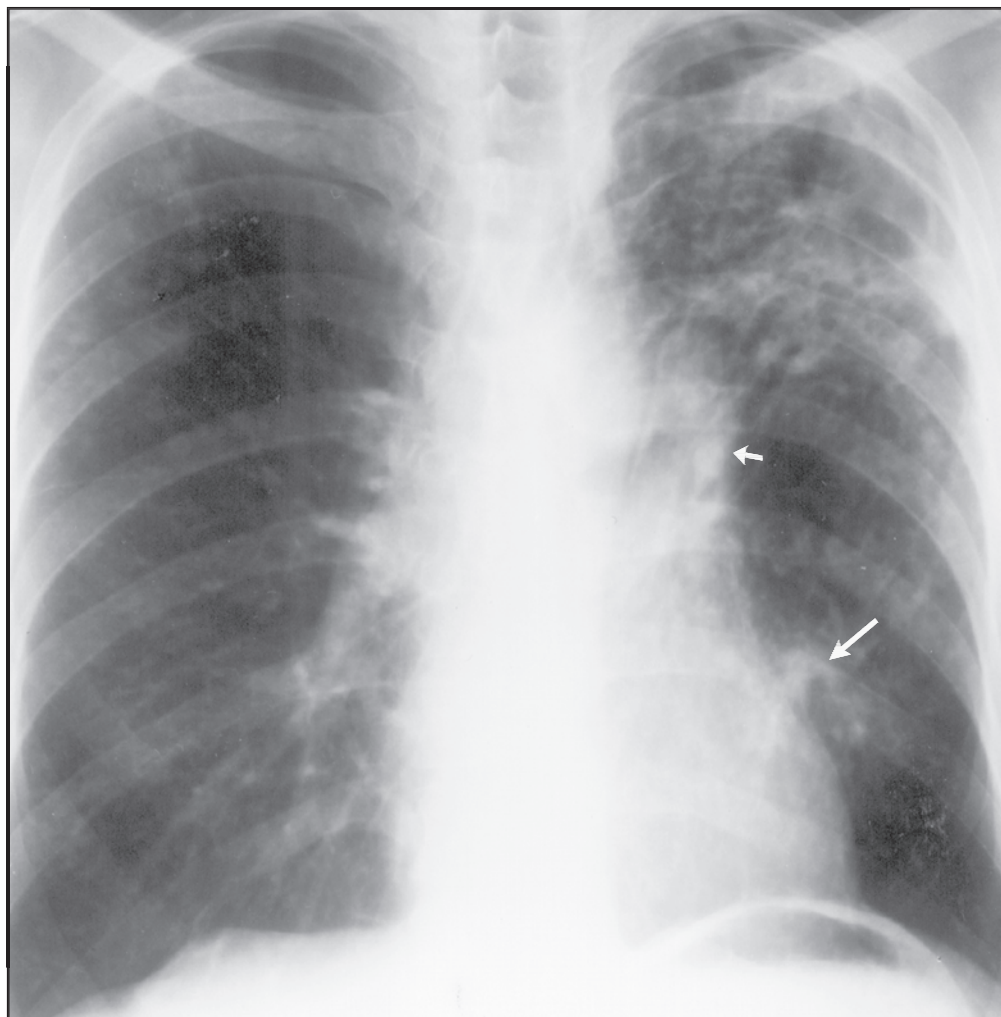
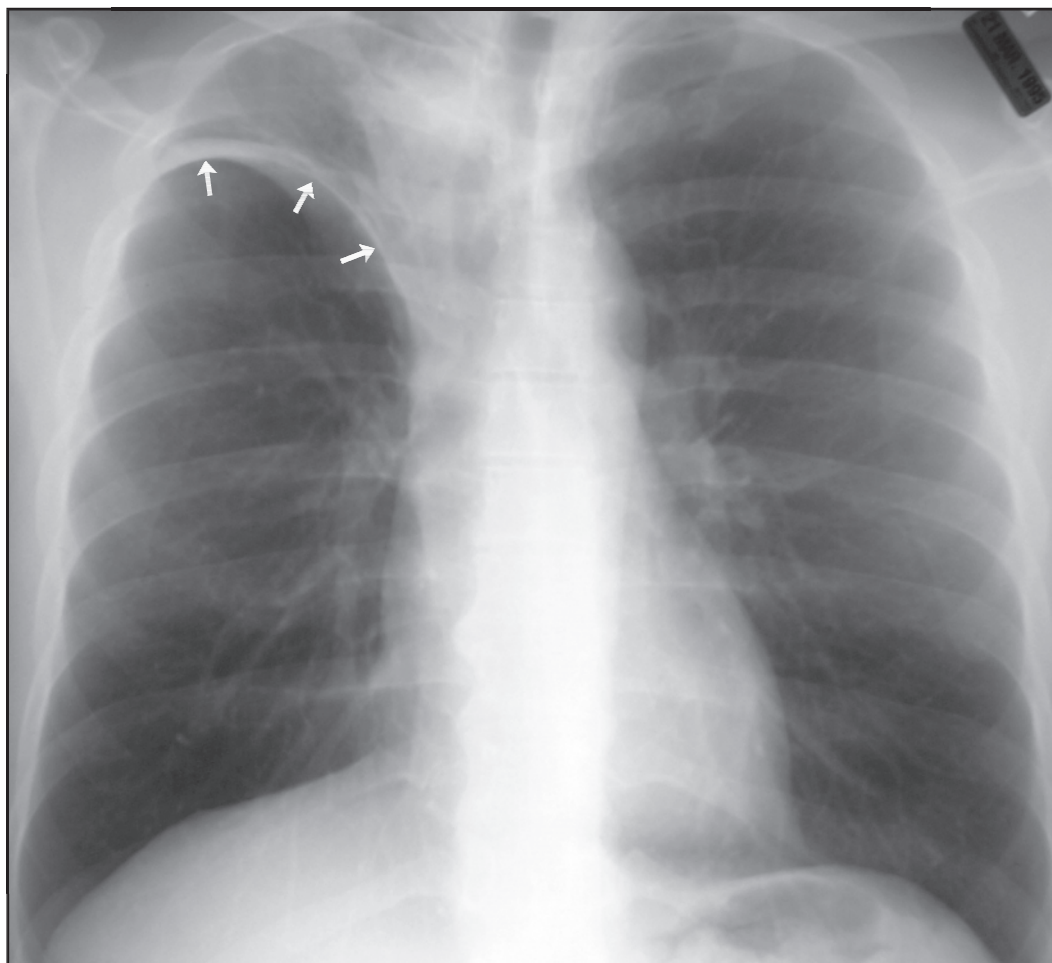


Figure 2.17 demonstrates airspace opacities and volume loss in the left upper lobe. The shift of the mediastinum and the left hilar elevation (small arrow) are signs of volume loss or atelectasis. Note the nodular opacity along the left heart border, which represents bronchogenic spread of tuberculosis (larger arrow).

- Post-primary tuberculosis is often associated with significant fibrosis. The resultant scarring can cause volume loss of the involved lung or lobe.
- Fibrotic lesions are often sharply defined and irregular in contour.
- These lesions are much more common in the upper lobes.
- Fibrotic lesions may be indicative of either active or prior tuberculosis, a distinction that can only be made by clinical and bacteriological evaluation.

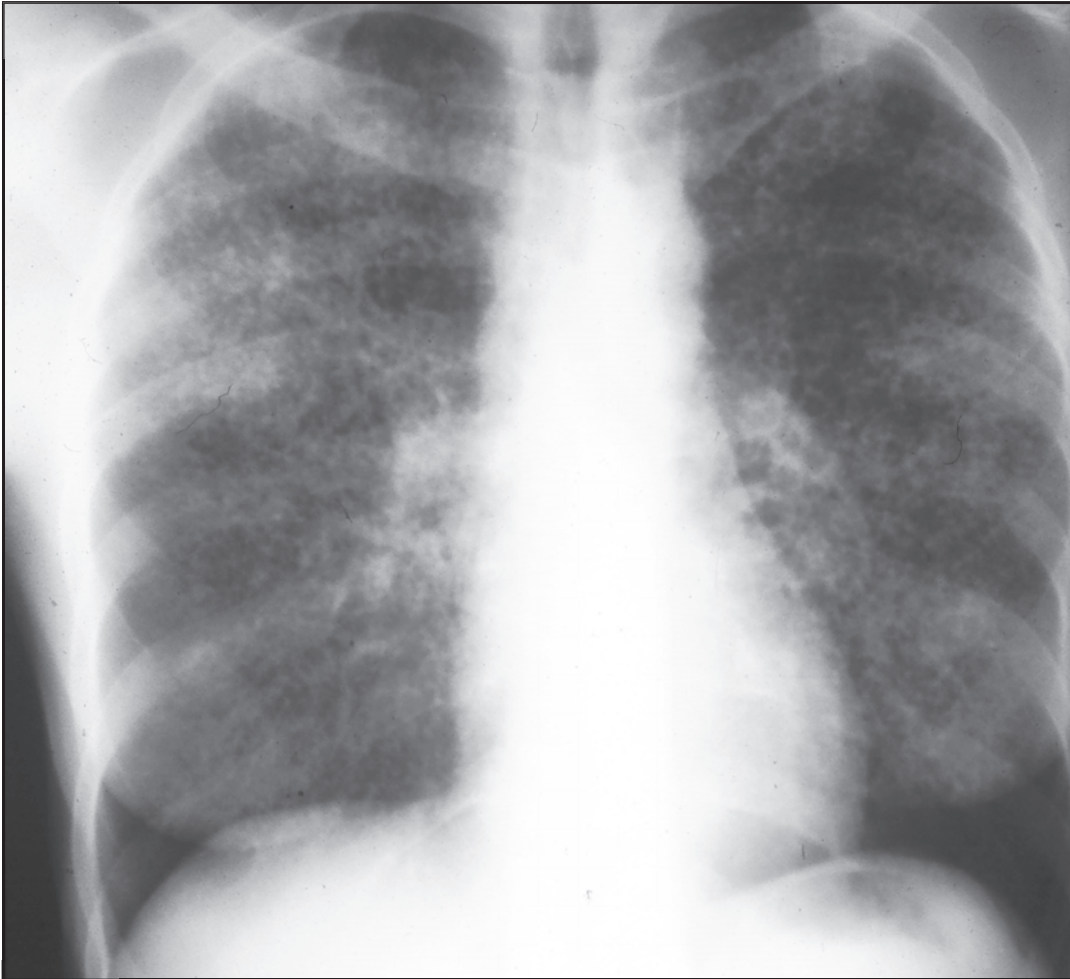**Figure 2.18: Bronchostenosis**



*Figure 2.18* shows a right upper lobe airspace opacity adjacent to the trachea. In addition, there is elevation of the minor fissure (arrows), indicating lung collapse and volume loss. A bronchoscopy was performed to rule out a coexisting endobronchial tumor. This patient with culture-confirmed tuberculosis was determined by bronchoscopy to have bronchostenosis.

## Interstitial Opacities (Miliary)

*Figure 2.19: Miliary Pattern*



*Figure 2.19* demonstrates bilateral diffuse small nodules characteristic of a miliary pattern.

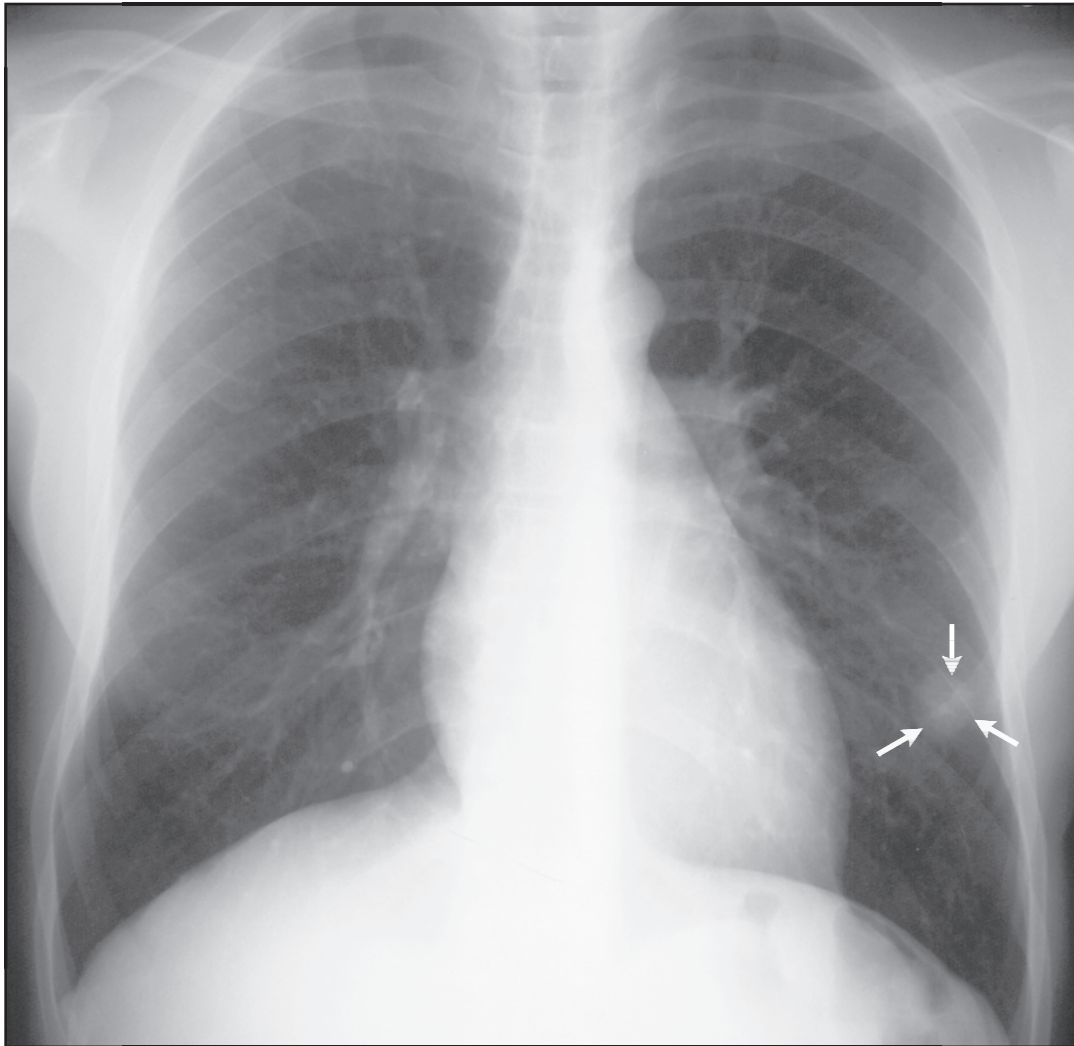
- A miliary pattern results from hematogenous dissemination of tubercle bacilli.
- This dissemination leads to many nodules of variable size, initially present in the interstitium and ultimately involving the airspaces.
- Most of the nodules in miliary tuberculosis are 2–3 mm in diameter.
- Because miliary nodules result from hematogenous dissemination, more are present in the lower lung zones, due to greater blood flow to the bases compared with the apices of the lungs.



## Tuberculoma

Tuberculomas are round or oval opacities, 1–5 cm in diameter, and usually found in the upper lobes. The pathophysiology of tuberculomas is unclear. Most experts believe that a tuberculoma represents a primary infection that has healed. Although they may remain stable for many years they can enlarge very slowly and eventually develop cavitation.

**Figure 2.20: Tuberculoma**



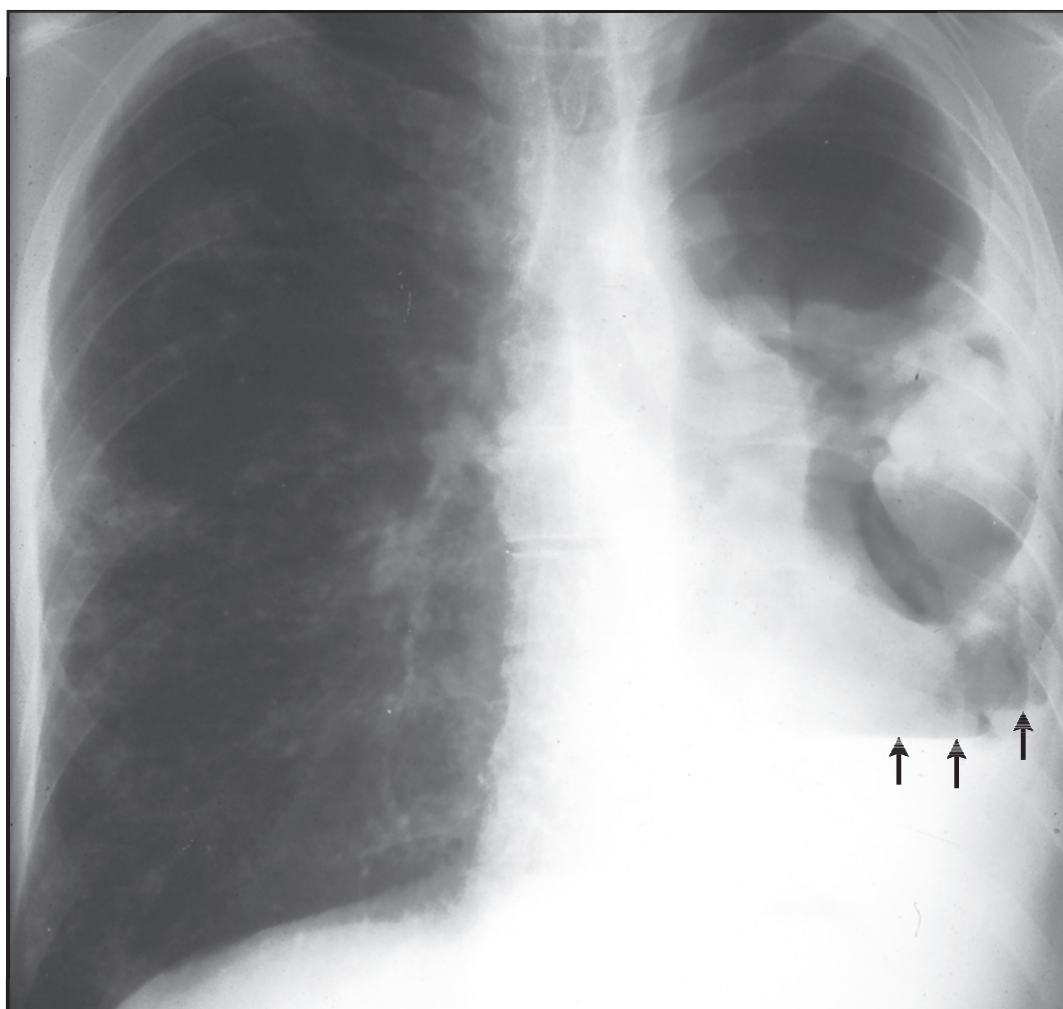
*Figure 2-20* demonstrates a well-circumscribed nodule in the left lower lobe (arrows). Note the dense calcification in the center of the nodule. Radiographically, tuberculomas can simulate a bronchogenic carcinoma.

- Tuberculomas are round or oval opacities, usually 1–5 cm in diameter, and usually found in the upper lobe.
- Tuberculomas are normally smooth and sharply defined.
- Satellite lesions, which are small, discrete nodules surrounding the tuberculoma, occur in 80% of cases and are clues to the diagnosis. However, they may only be visible on high-resolution CT.

## Pleural Disease

Pleural effusions can be a manifestation of primary or post-primary tuberculosis. However, in post-primary disease, the effusion is more likely to be associated with radiographically visible parenchymal abnormalities. Rarely, the effusion is a frank tuberculous empyema. You saw examples of simple tuberculous pleural effusions earlier in *Figures 2.3* and *2.12*.

**Figure 2.21: Tuberculous Empyema**



*Figure 2.21* shows an example of a tuberculous empyema that developed when a cavitary tuberculous pneumonia ruptured into the pleural space, creating a bronchopleural fistula. This case demonstrates a left pleural effusion with air-fluid levels (arrows) consistent with a hydropneumothorax caused by the bronchopleural fistula.

- Diagnosis of hydropneumothorax is based on the presence of a pleural effusion accompanied by an air-fluid level within the pleural space.
- The term hydropneumothorax signifies communication of the pleural space with the bronchial tree. Hydropneumothorax is often due to a necrotizing pneumonia such as tuberculosis.



## ***Tuberculosis and HIV Infection***

The radiographic manifestations of HIV-related tuberculosis vary depending on the degree of immunosuppression. In an HIV-infected patient whose immune system is relatively intact (i.e., >200 CD4 cells/ $\mu$ L), the radiographic manifestations of tuberculosis represent those seen in post-primary disease.

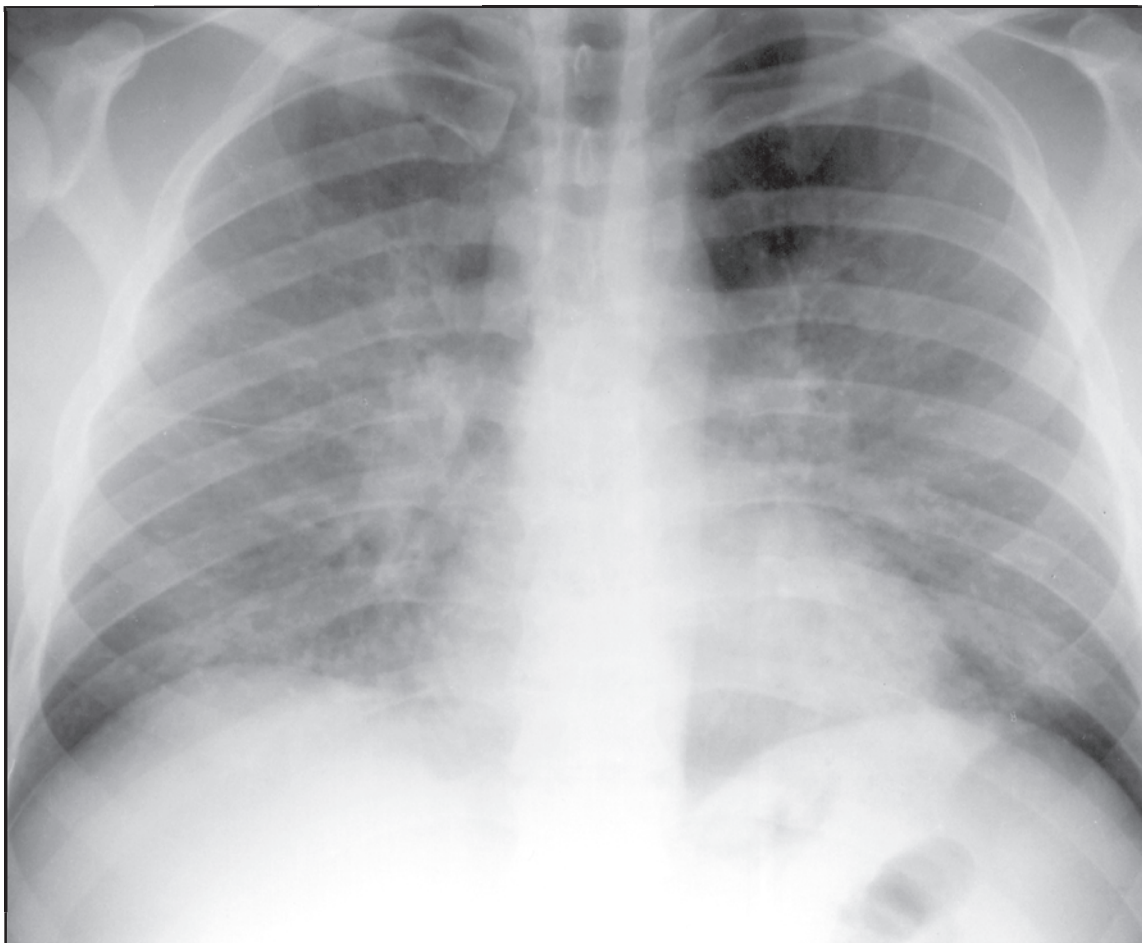
- The opacities occur in the upper lobe.
- Cavitation may be present.
- Thoracic adenopathy is uncommon.

As the CD4 lymphocyte count declines, the radiographic findings look more like those seen in primary disease.

- The radiographic opacities may be in the lower lung zones and multilobar in nature.
- Thoracic adenopathy is more common.

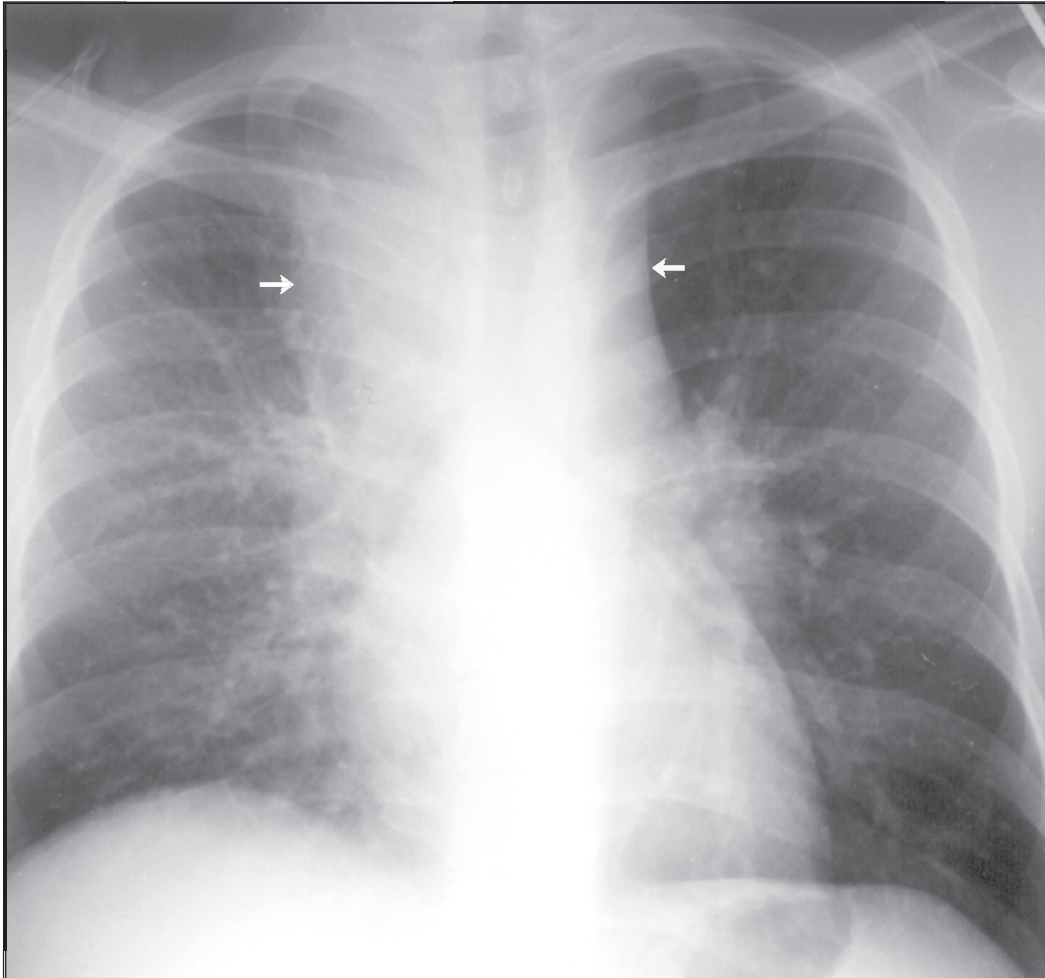
Following are three examples of unusual (atypical) radiographic manifestations of HIV-related tuberculosis.

***Figure 2.22: Bilateral Diffuse Opacities***



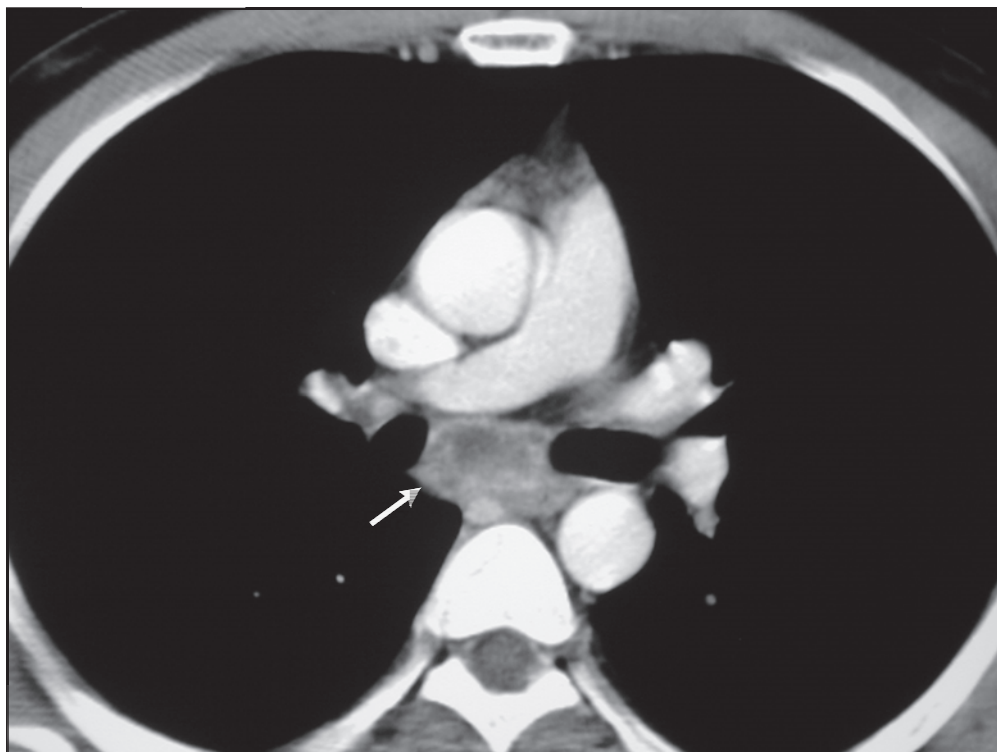
*Figure 2.22 demonstrates bilateral diffuse opacities, primarily of the airspaces, with bilateral hilar adenopathy. The patient had AFB smear-positive tuberculosis.*

**Figure 2.23: Large Paratracheal Adenopathy**



*Figure 2.23* demonstrates large bilateral paratracheal adenopathy, causing widening of the mediastinum (arrows) with right middle and lower lung zone airspace and linear opacities. Note loss of the normal aortopulmonary window contour. Despite radiographically limited parenchymal disease, the patient was AFB smear-positive.

**Figure 2.24: Mediastinal Adenopathy**



*Figure 2.24*, a CT image, demonstrates mediastinal adenopathy (arrow) with central low attenuation (darkening) due to necrosis. This finding is highly predictive of mycobacterial infection, particularly tuberculosis.

## ***Resolution of Radiographic Abnormalities and Healed Tuberculosis***

The chest abnormalities seen by radiography in tuberculosis are slow to resolve. In many cases, parenchymal opacities and thoracic adenopathy actually worsen before improving. For this reason, the chest radiograph is not the best way to follow the response to antituberculosis therapy. Instead, a clinical assessment should be performed and a bacteriological response to therapy should be monitored in order to determine if the patient is or is not improving with treatment.

### ***Primary Tuberculosis***

---

Healing of the primary complex, with or without therapy, can result in fibrosis and calcification of the Ghon focus. The Ghon focus is represented radiographically as a calcified nodular opacity on the chest radiograph (e.g., calcified granuloma). The Ghon focus, in combination with a calcified ipsilateral hilar or mediastinal calcification, are the radiographic manifestations of the Ranke Complex.

Primary tuberculosis typically resolves with minimal fibrosis and volume loss. However, patients who develop progressive primary disease with cavitation may suffer significant fibrosis and may develop bronchiectasis, similar to post-primary disease. Lymphadenopathy may take months to resolve and, in some cases, there may be prolonged enlargement of lymph nodes, particularly in children.

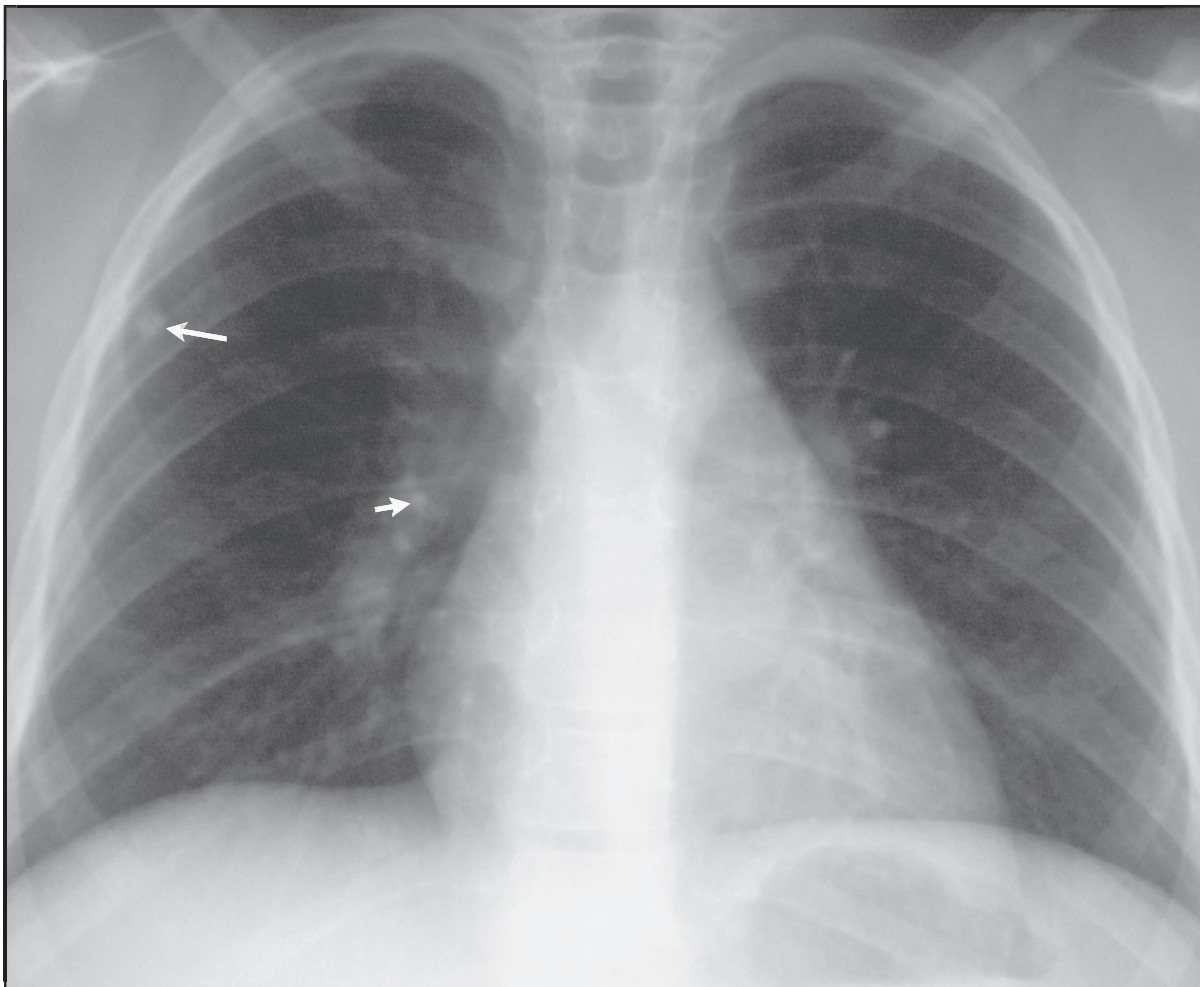
### ***Post-primary Tuberculosis***

---

The degree of fibrosis and scarring varies considerably with post-primary tuberculosis. In general, the more extensive the disease and the worse the cavitation, the more likely it is that there will be fibrosis with associated volume loss. It is important to note that fibrosis and volume loss can occur in the presence of active tuberculosis, so these findings should not be used to dismiss a diagnosis of active disease.

Following are examples of healed primary and post-primary tuberculosis.

**Figure 2.25: Ranke Complex**

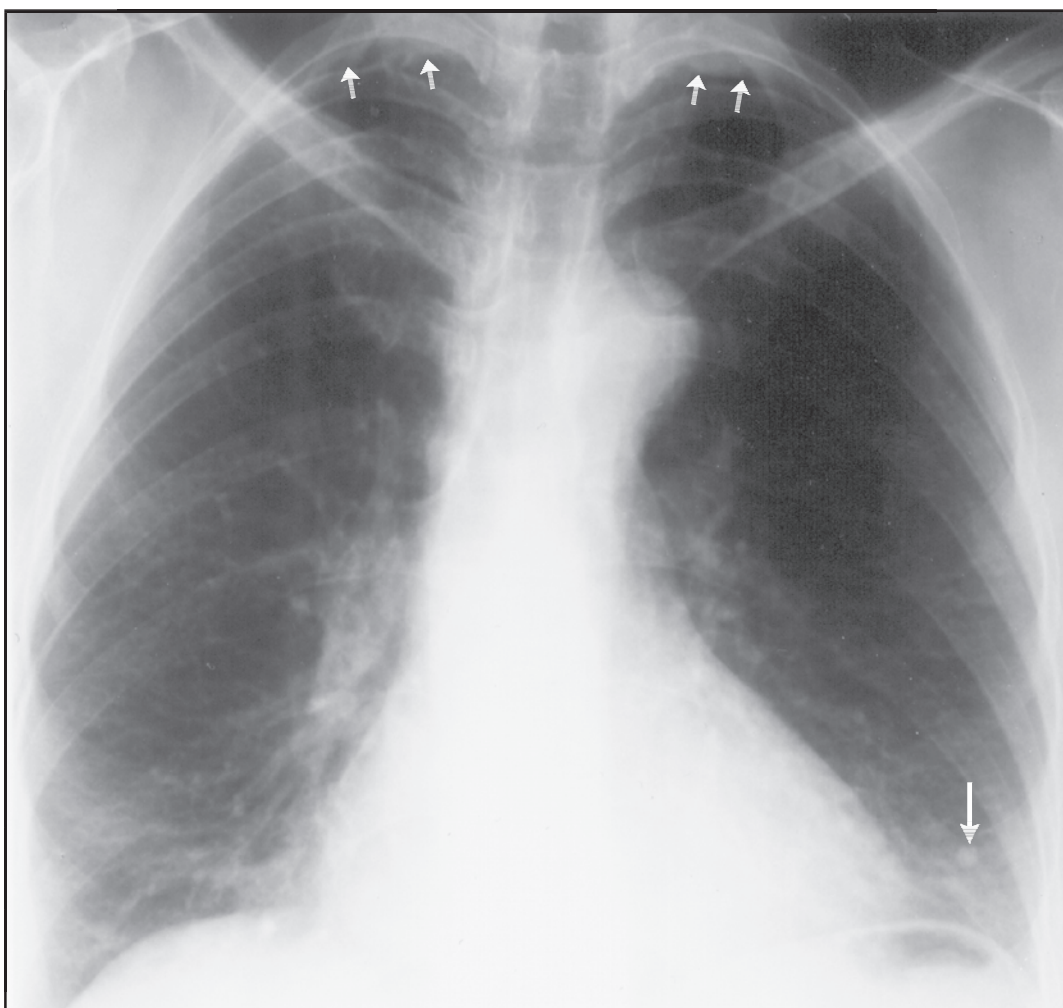


*Figure 2.25* demonstrates a calcified peripheral nodular opacity (large arrow) consistent with a Ghon lesion. There is also a calcified right hilar node (small arrow). Together, these lesions are referred to as a Ranke complex.

- A Ghon lesion represents a calcified granuloma in the lung parenchyma.
- A Ranke complex is the combination of a Ghon lesion and an ipsilateral calcified hilar lymph node.
- Neither a Ghon lesion nor Ranke complex represent active tuberculosis.
- Isolated calcified granulomas are not associated with an increased risk of progression to active disease in people with latent tuberculosis infection.



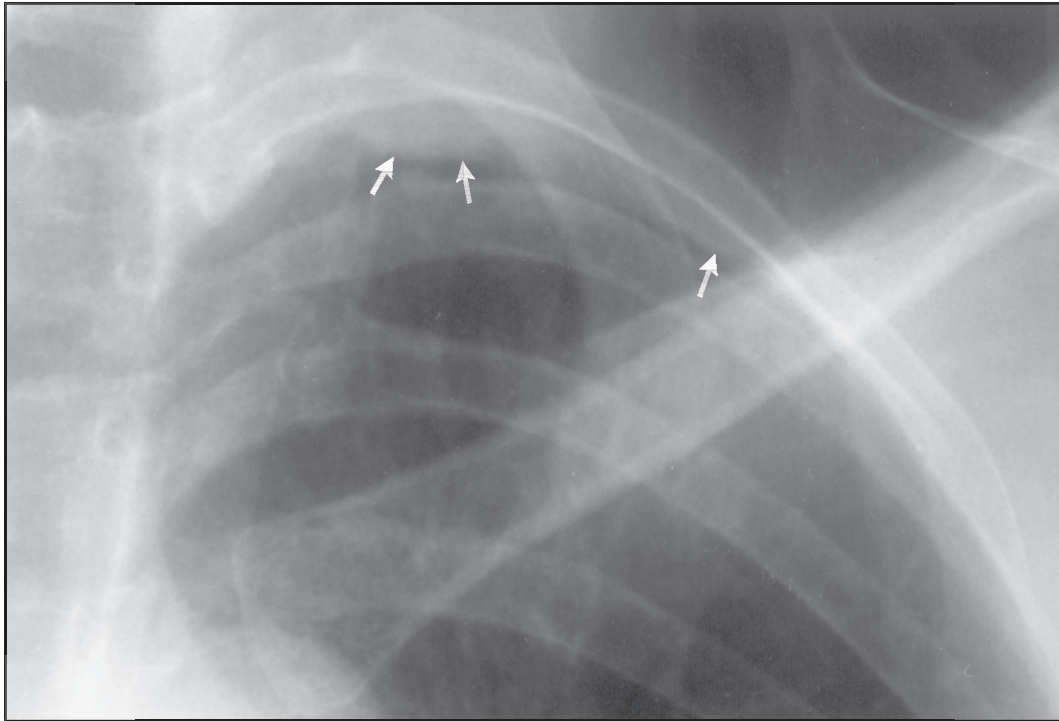
**Figure 2.26a: Previously Treated Pulmonary Tuberculosis**



*Figure 2.26a* depicts a patient who had been treated previously for pulmonary tuberculosis. The patient has a calcified nodule (large arrow) consistent with a calcified granuloma. In addition, there is bilateral apical pleural thickening (small arrows). See also *Figure 2.26b*.



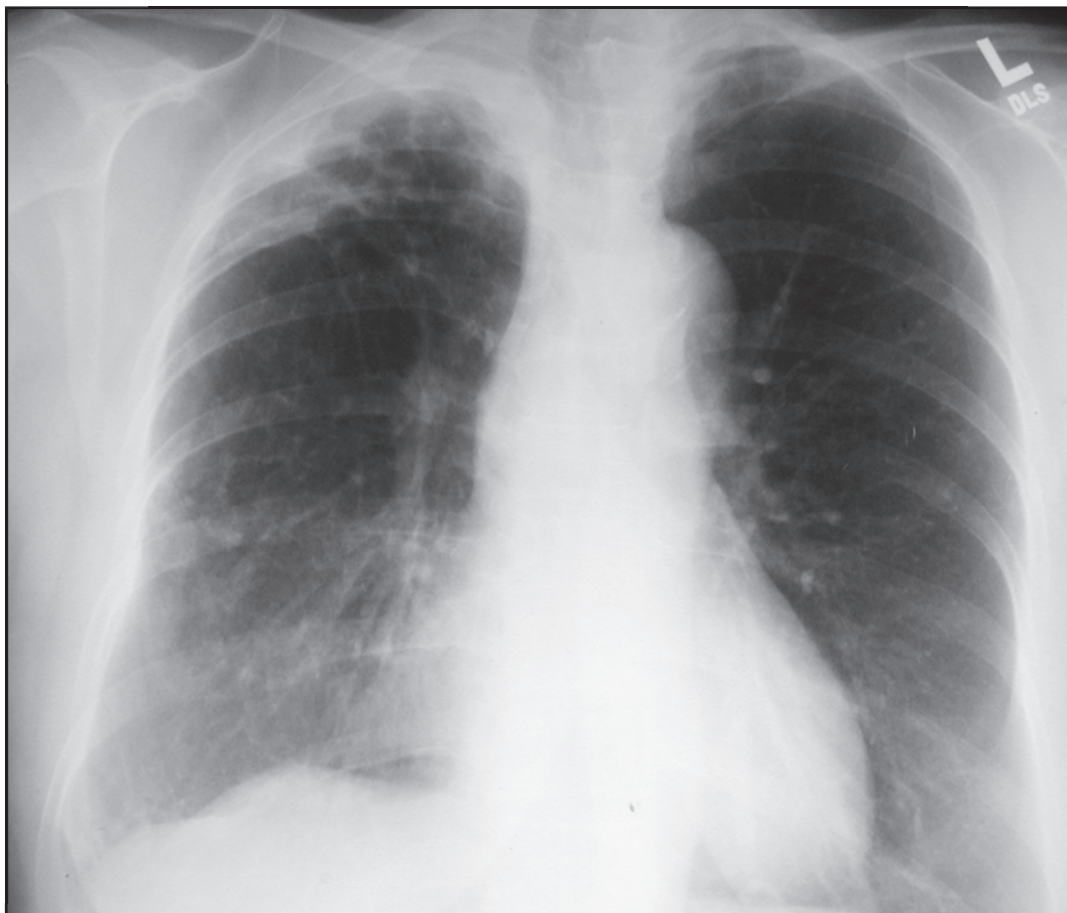**Figure 2.26b: Apical Pleural Thickening**



*Figure 2.26b* depicts a close-up view of the left apex seen in *Figure 2.26a*, demonstrating apical pleural thickening (arrows).

- Apical pleural thickening may be seen with or without surrounding apical parenchymal opacities.
- Apical pleural thickening is not associated with active tuberculosis unless there are also accompanying parenchymal opacities such as airspace consolidation, nodules, or fibrosis.
- Isolated pleural thickening is not associated with an increased risk of progression to active disease in people with latent tuberculosis infection.

**Figure 2.27: Fibrotic Scarring**



*Figure 2.27* demonstrates right upper lobe linear opacities, apical pleural thickening, and volume loss. Note the elevation of the right hilum and hemidiaphragm. This patient was asymptomatic and had negative AFB smears and cultures.

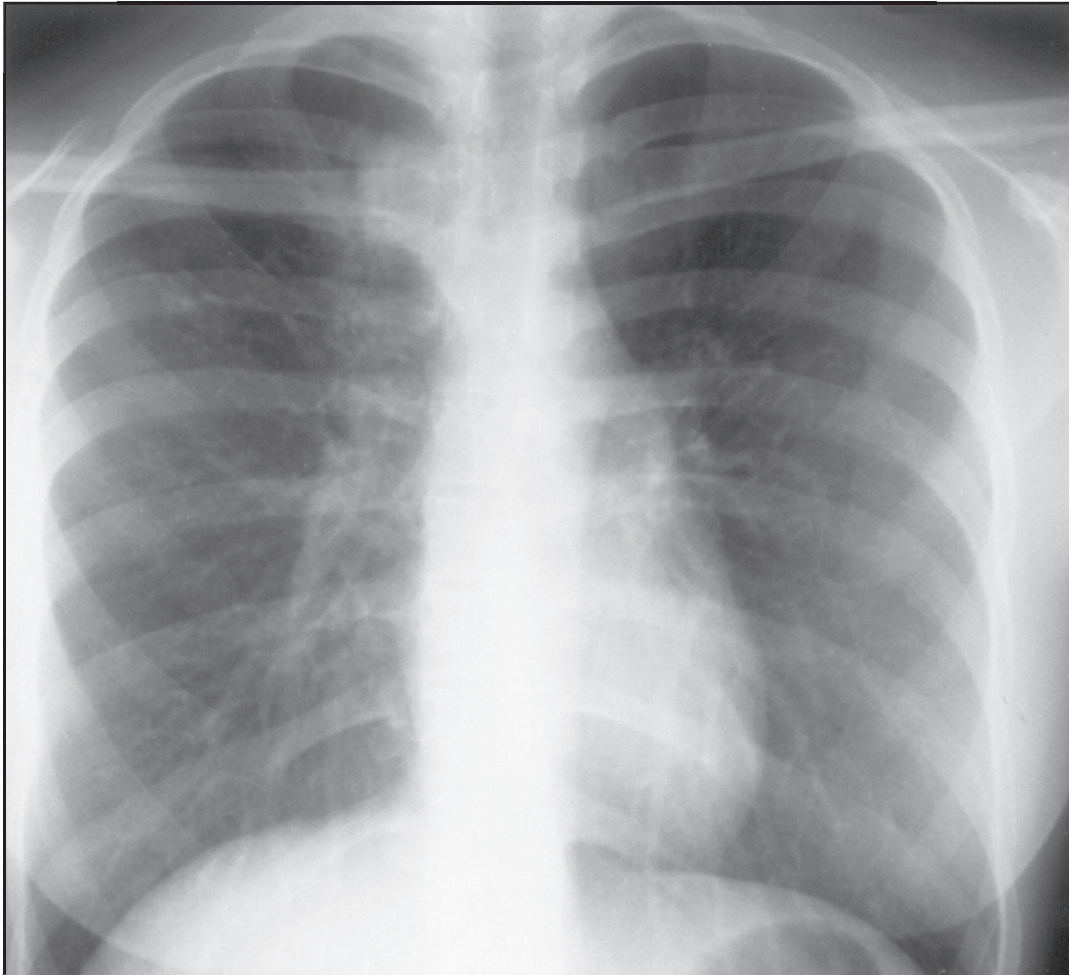
- Post-primary tuberculosis is often associated with significant fibrosis. The resultant scarring can cause volume loss of the involved lung or lobe.
- Fibrotic lesions may indicate either active or prior tuberculosis. This distinction can only be made by clinical and microbiological evaluation.
- The presence of parenchymal opacities—representing old healed tuberculosis—increases the risk of progression to tuberculosis in individuals who have received inadequate prior treatment for tuberculosis or latent tuberculosis infection.

## ***Self-Check Three***

The following self-check has three chest radiographs to analyze and three multiple choice questions. After completing the self-check, look at the answers beginning on page 2-41. Review the material in the previous pages to clarify any answers you have missed.

1. Describe the chest radiograph below in *Figure 2.28*.

***Figure 2.28***



Description:

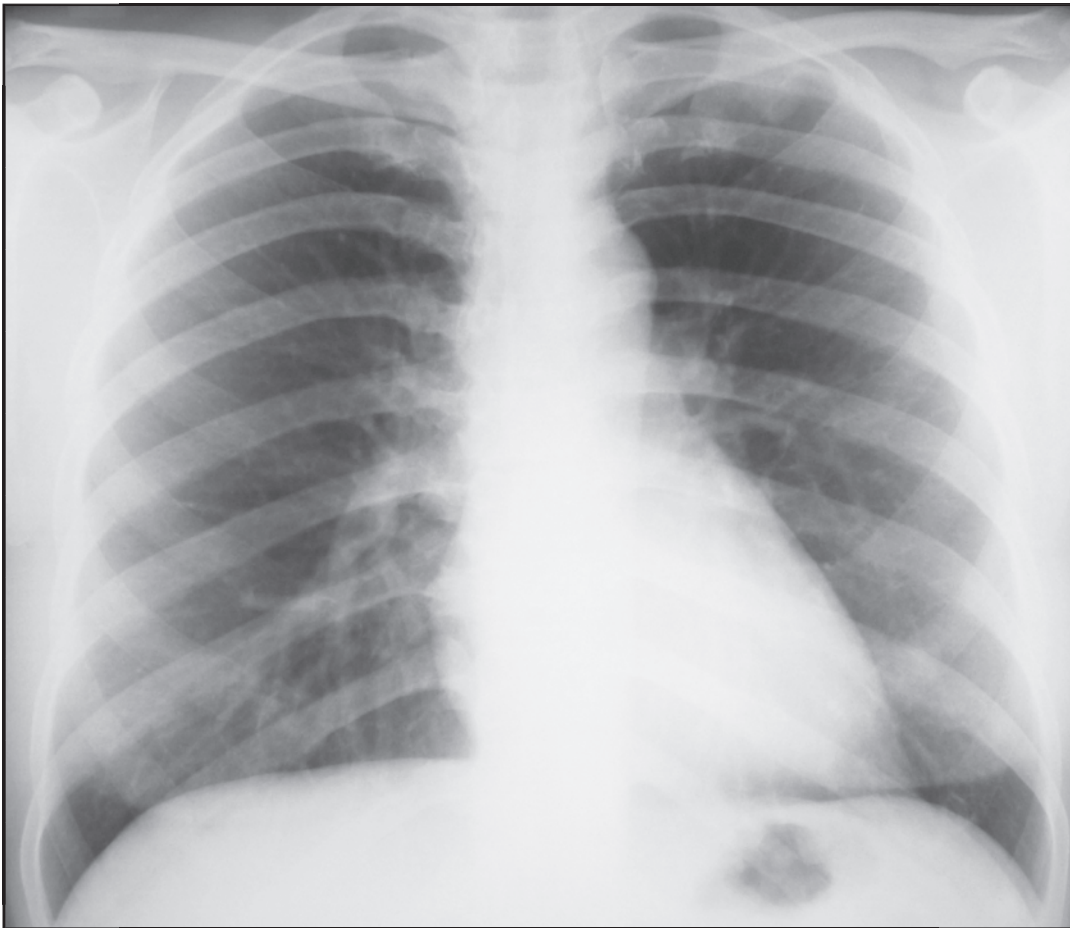
---

---

---

2. Describe the chest radiograph below in *Figure 2.29*.

**Figure 2.29**



Description:

---

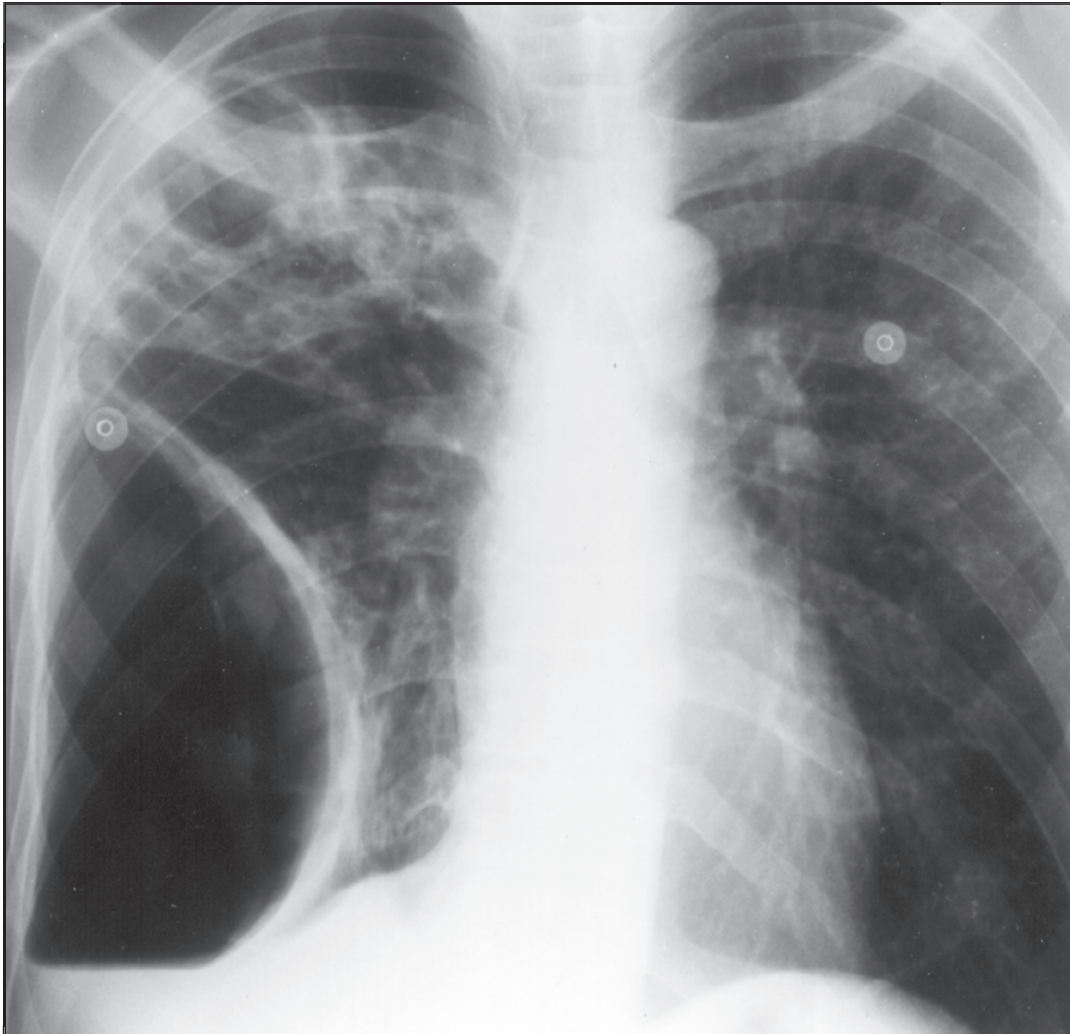
---

---

## ***Self-Check Three (continued)***

**3.** Describe the chest radiograph in *Figure 2.30*.

***Figure 2.30***



Description:

---

---

---

---

- 4.** Which of the following radiographic manifestations is most consistent with active primary tuberculosis in an adult?
- A.** Upper lobe, posterior segment involvement
  - B.** Bronchopleural fistula
  - C.** Calcified granuloma
  - D.** Pleural effusion
- 5.** Which of the following radiographic manifestations of tuberculosis is more common in HIV-infected adults than in HIV-uninfected adults?
- A.** Hilar adenopathy
  - B.** Pleural effusion
  - C.** Upper lobe opacities
  - D.** Calcified granuloma
- 6.** The most common parenchymal pattern of disease of both primary and post-primary (reactivation) tuberculosis is:
- A.** Miliary pattern
  - B.** Pleural effusion
  - C.** Airspace consolidation
  - D.** Cavitation



## ***Conclusion***

Now that you have completed this chapter, you should be able to identify the various radiographic manifestations of tuberculosis and use the terminology learned in Chapter One to describe your findings.

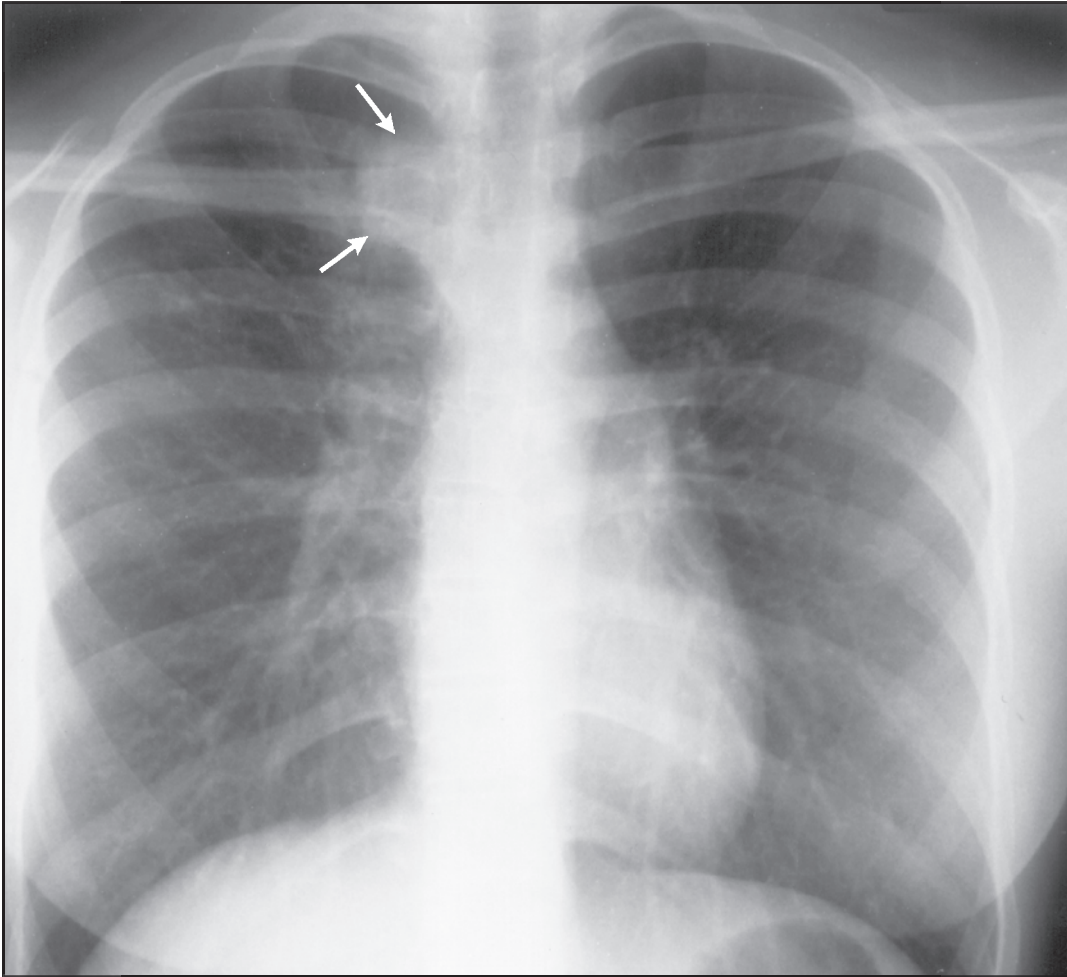
In the next chapter, you will review several clinical cases and use the knowledge and skills that you have developed in the first two chapters to read chest radiographs and make clinical decisions based on your interpretation.

## ***Self-Check Three Answers***

**1. Description:**

There is a right paratracheal opacity behind the right clavicle in *Figure 2.31* (see arrows).  
This patient had culture-confirmed tuberculosis.

***Figure 2.31***

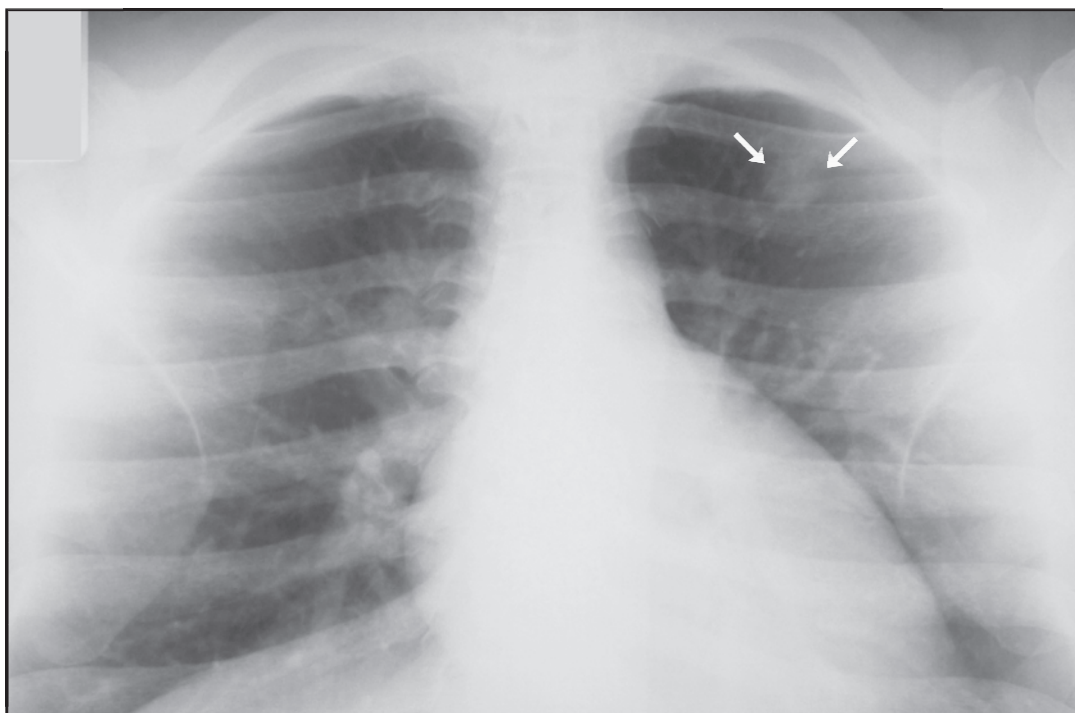


## ***Self-Check Three Answers (continued)***

### **2. Description:**

There is a nodular density overlying the left first rib in *Figure 2.29*. This patient radiograph was taken in the apical lordotic view, allowing demonstration of the left upper lobe nodular density (arrows).

***Figure 2.32***

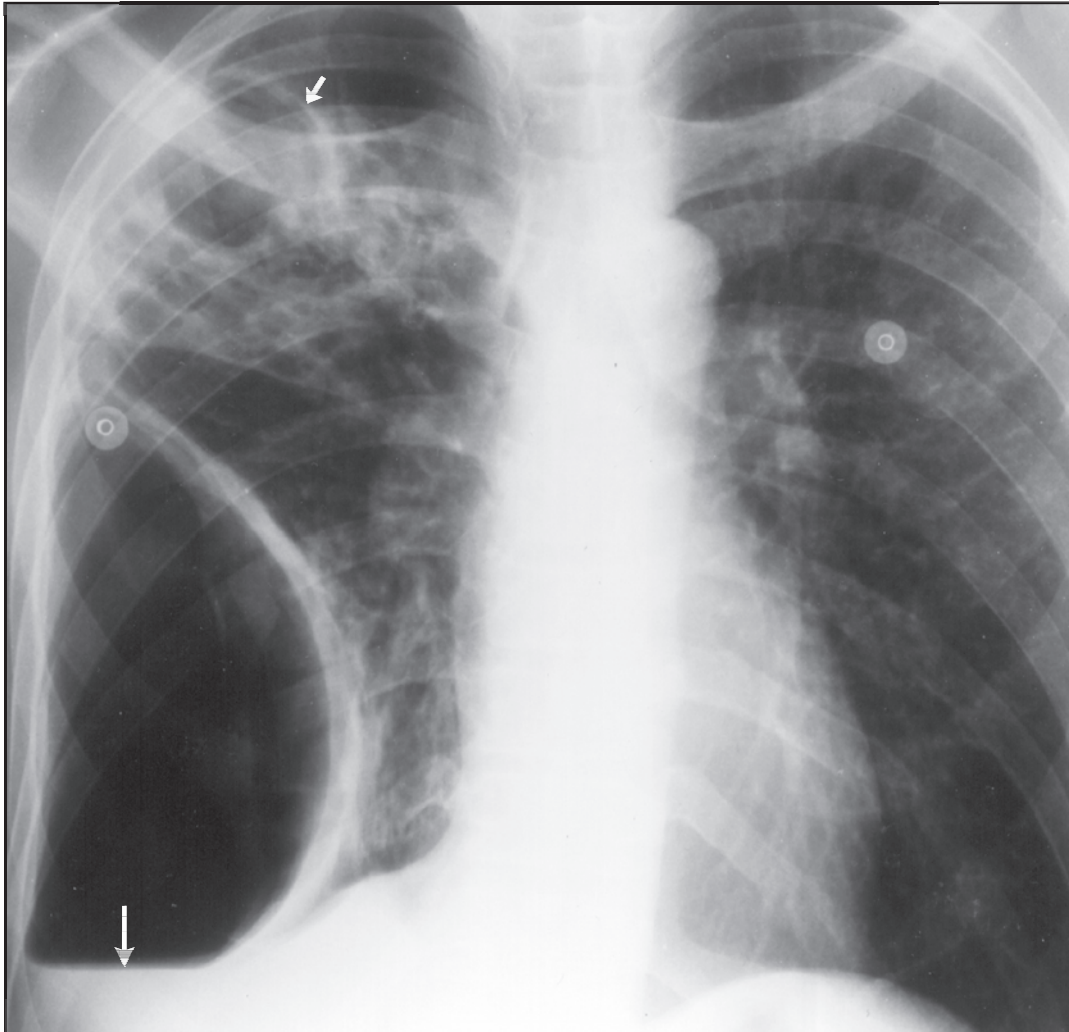


**3. Description:**

*Figure 2.33* demonstrates a right upper lobe airspace opacity with cavitation.

Note the large cavity (small arrow). There is also a large right hydropneumothorax with an air-fluid level (large arrow). This patient had smear-positive pulmonary tuberculosis and a tuberculous empyema.

***Figure 2.33***



## ***References***

Fraser RS, Pare JAP, Fraser RG, Pare PD. Infectious diseases of the lungs. In: Fraser RS, Pare JAP, Fraser RG, Pare PD, eds. *Synopsis of Diseases of the Chest*. 2nd ed. Philadelphia, PA: WB Saunders; 1994:315-332.

Jones BE, Ryu R, Yang Z, et al. Chest radiographic findings in patients with tuberculosis with recent or remote infection. *Am J Respir Crit Care Med*. 1997;156:1270-1273.

Leung AN. Pulmonary tuberculosis: the essentials. *Radiology*. 1999;210:307-322.

McAdams HP, Erasmus J, Winter JA. Radiologic manifestations of pulmonary tuberculosis. *Radiol Clin North Am*. 1995;33:655-678.

Palmer PE. Pulmonary tuberculosis--usual and unusual radiographic presentations. *Semin Roentgenol*. 1979;14:204-43.

Rich AR. The pathogenesis of pulmonary tuberculosis. In: Rich AR, ed. *The Pathogenesis of Pulmonary Tuberculosis*. Springfield, Ill: Charles C. Thomas Publisher; 1944.

Woodring JH, Vandiviere HM, Fried AM, Dillon ML, Williams TD, Melvin IG. Update: the radiographic features of pulmonary tuberculosis. *Am J Roentgenol*. 1986;146:497-506.

**CHAPTER THREE**

# ***Clinical Cases***

## ***Introduction***

In the first chapter, we provided a framework for approaching chest radiographs and characterizing abnormalities using standard terminology. In the second chapter, we showed examples of the many chest radiographic abnormalities that can be seen in patients with tuberculosis. In this chapter, our goal is to integrate what you have learned thus far and apply that knowledge to clinical cases.

These cases are from our own practice, but include examples of clinical problems and decision-making challenges that are applicable to any clinician diagnosing and treating tuberculosis.

In each case you will be asked to describe the radiographic abnormalities and answer questions relevant to the evaluation and treatment of the case. All of the questions are brief essay or multiple choice. The answers to the questions and a summary immediately follow each case. We suggest completing each case before checking your answers.

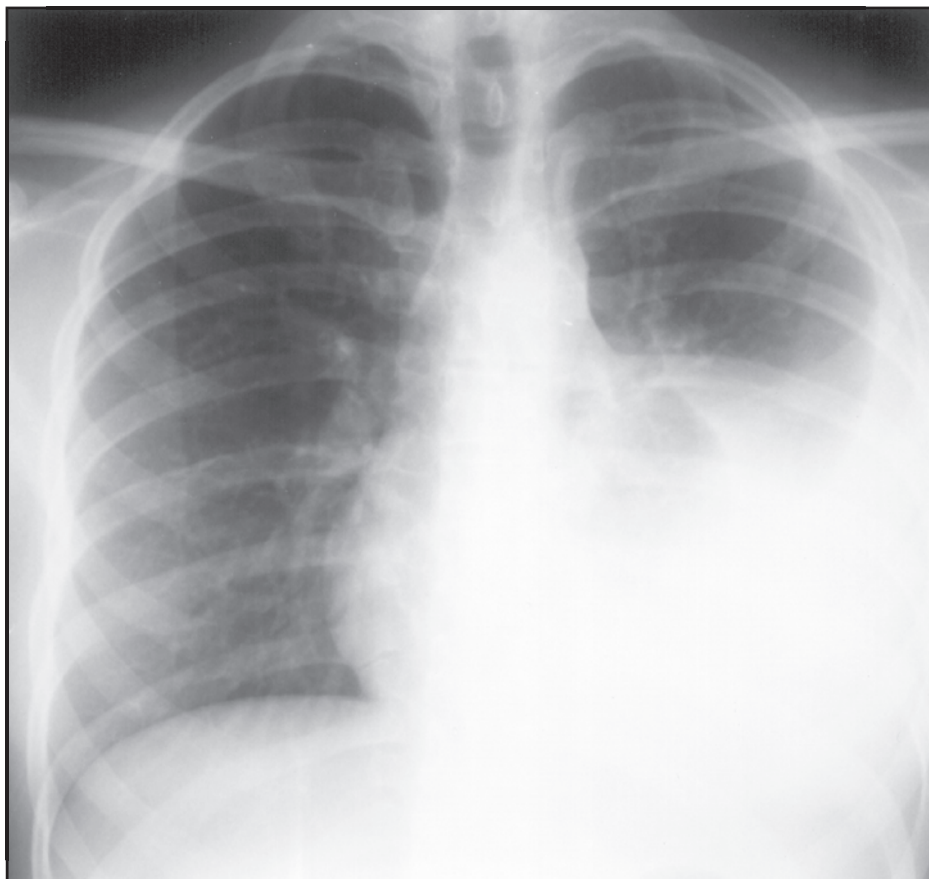




## Case One

The patient is a 27-year-old woman who was born in Pakistan and moved to the United States at age 3. She noted two weeks of pleuritic chest pain, fevers, night sweats, and a nonproductive cough for 5 days. The patient had spent the past 2 years working with the poor in India, Egypt, and Ethiopia. Her tuberculin skin test was 3 mm 2 years ago and now is 14 mm. Her chest radiograph is shown in *Figure 3.1*.

**Figure 3.1**



1. Describe the chest radiograph in *Figure 3.1* using standard terminology.
  
2. Which of the following should be done next?
  - A. Bronchoscopy
  - B. Thoracoscopic lung biopsy
  - C. Thoracentesis
  - D. Isoniazid treatment of latent tuberculosis infection

## Case One Answers

---

1. Homogeneous opacity occupying more than one-half of the left hemithorax and extending up the lateral chest wall. The opacity is obscuring the left hemidiaphragm.

XXXXXXXXXXXXXXXXXXXX

## Case One Summary

---

A thoracentesis was performed and demonstrated a white blood cell count of 1,500 cells/ $\mu$ L (80% of which were mononuclear cells), a normal glucose, and an elevated protein concentration. No acid-fast bacilli were noted. Gram's stain and bacterial and mycobacterial cultures were negative. Three sputum specimens were negative for acid-fast bacilli. A closed left-sided pleural biopsy was performed. *M. tuberculosis* was isolated from tissue cultured from the pleural biopsy.

The patient was started on a standard four-drug antituberculosis regimen but her treatment was altered when she was discovered to have disease due to an isoniazid-resistant organism. This would not have been known had a pleural biopsy not been performed. She was treated with rifampin, pyrazinamide, and ethambutol for six months. The pleural effusion resolved with anti-tuberculosis chemotherapy.

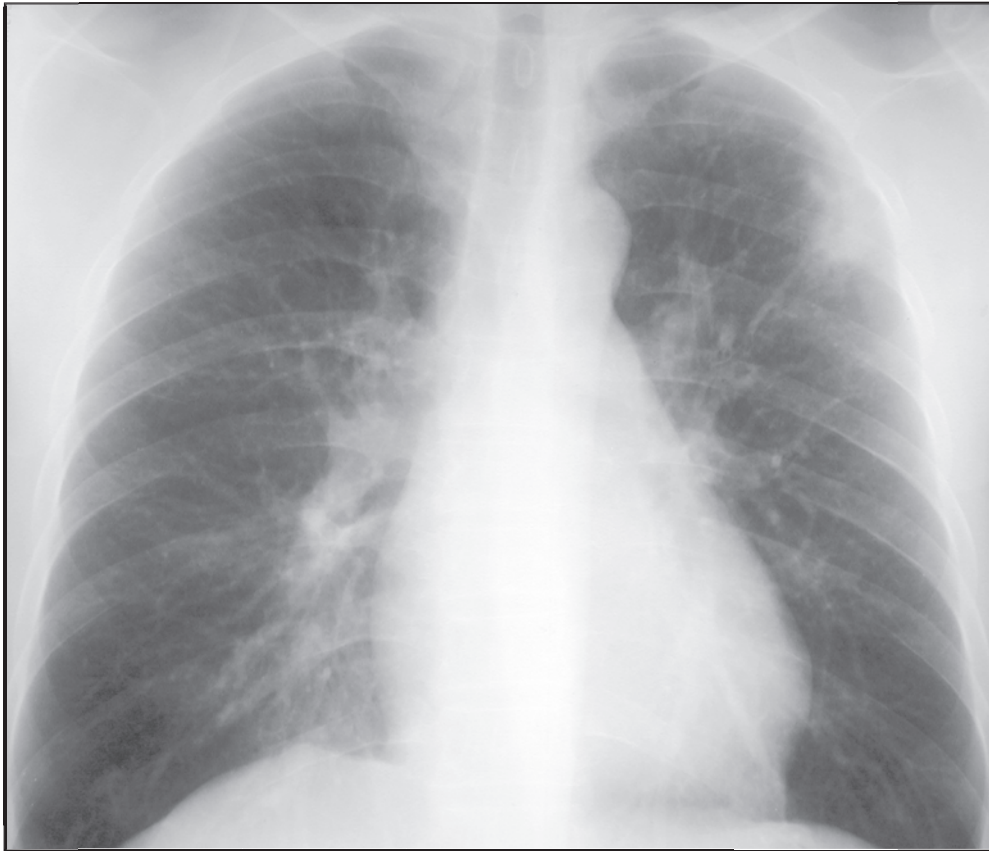Pleural tuberculosis represents one of the most common forms of extrapulmonary tuberculosis. It is characterized by a lymphocytic pleural effusion that is an exudate. The diagnosis can be difficult to establish because sputum and pleural liquid cultures are often negative (culture yield <50%). Diagnosis is best accomplished by a pleural biopsy and sending the specimen for both histological examination and mycobacterial culture.

Although it is reasonable to treat empirically for tuberculosis in a patient having a positive tuberculin skin test and an exudative pleural effusion without another known cause, making a definitive diagnosis is preferable because it allows you to determine whether drug-resistant organisms are present and excludes other diagnoses that might require alternative treatment.

## Case Two

The patient is a 30-year-old Asian woman who was noted to have an abnormal chest radiograph (*Figure 3.2*) when she underwent tuberculosis evaluation prior to employment in a healthcare facility. The patient had a tuberculin skin test with 12 mm induration several years earlier for which she received 6 months of isoniazid. She denies having symptoms, has no underlying medical conditions, and is a non-smoker.

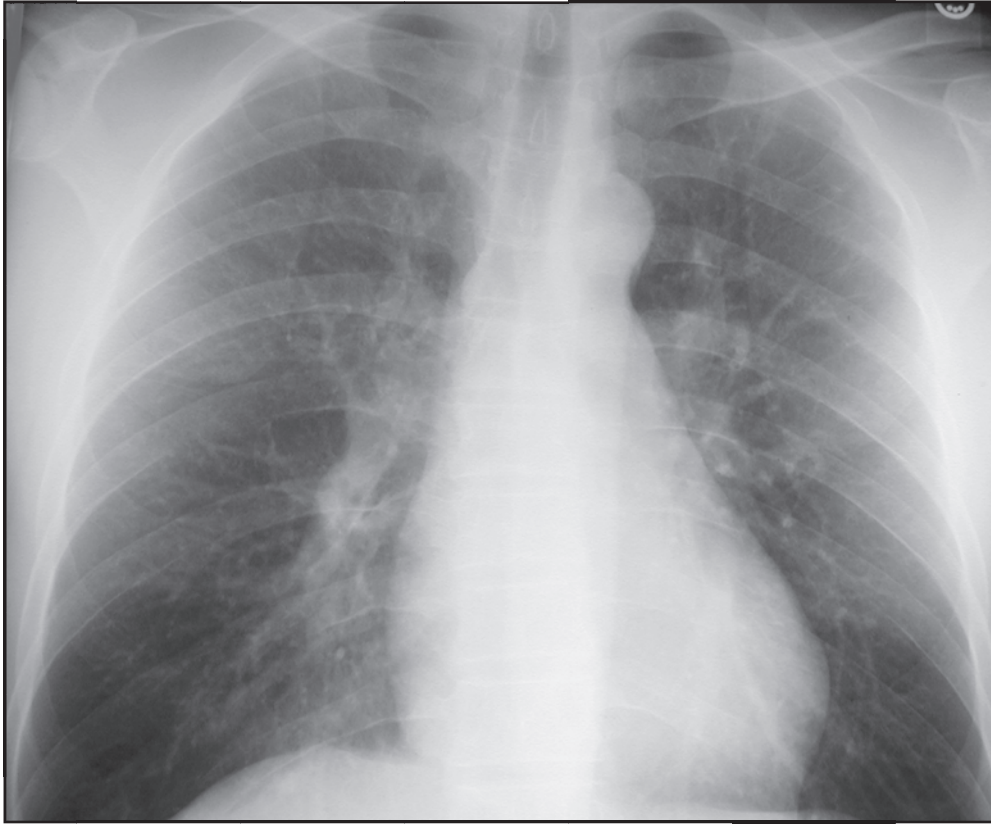
**Figure 3.2**



1. How would you describe the chest radiograph in *Figure 3.2*?
2. Based on your reading of the chest radiograph, which of the following is the **most** appropriate next step?
  - A. Collect three sputum specimens for acid-fast smears and mycobacterial cultures
  - B. Begin treatment for latent tuberculosis infection with isoniazid
  - C. Repeat the tuberculin skin test
  - D. Repeat the chest radiograph in 6 months

The patient was started on four antituberculosis medications pending the results of sputum cultures. After 2 months, the culture results were negative. A repeat chest radiograph was obtained (*Figure 3.3*).

***Figure 3.3 - after 2 months of treatment for tuberculosis***



**3.** How would you describe the chest radiograph in *Figure 3.3*?

4. Which of the following would be the **most** appropriate next step?

- A.* Continue multidrug therapy for tuberculosis
- B.* Obtain a chest CT scan
- C.* Perform a fine-needle aspiration of the nodule
- D.* Perform bronchoscopy to obtain a better respiratory specimen



## ***Case Two Answers***

---

1. There is a left upper lobe peripheral airspace opacity.
2. Left upper lobe peripheral opacity is nearly resolved compared with the chest radiograph from 2 months ago.

## ***Case Two Summary***

---

In a patient at risk for tuberculosis who has an abnormal chest radiograph consistent with tuberculosis, the first step should be to obtain sputum for acid-fast smears and mycobacterial cultures to assess whether active tuberculosis is present. Sputum examination for tuberculosis is necessary because it is impossible to gauge the clinical activity of tuberculosis on the basis of a single radiograph. In addition, multidrug treatment should be given if there is a significant suspicion that active tuberculosis is present. If the diagnosis is confirmed by a positive culture, treatment can be continued to complete a standard course of therapy.

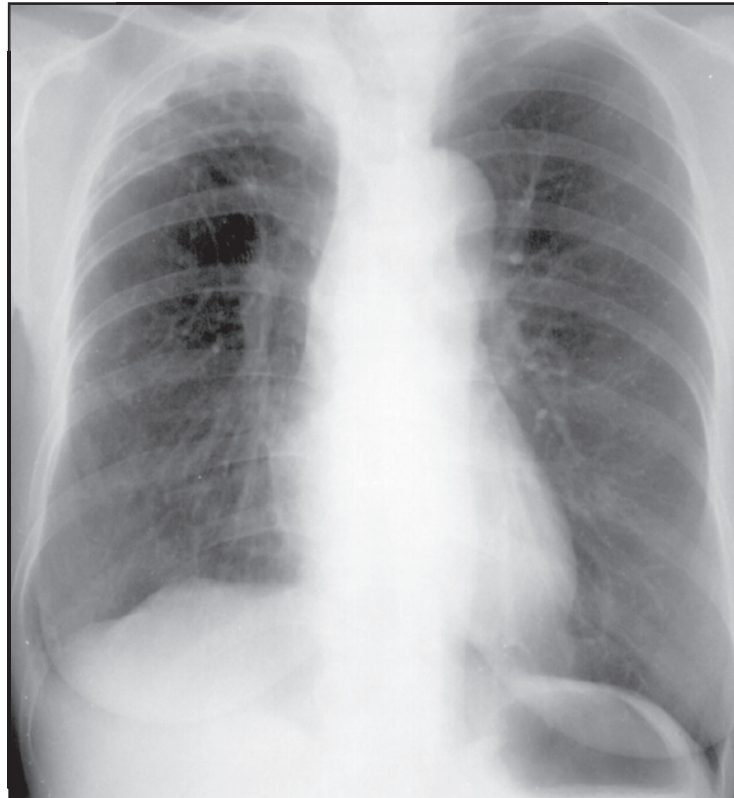Negative cultures do not necessarily exclude a diagnosis of active tuberculosis; up to 15% of cases in the United States may be culture-negative. The low bacillary load in nodules compared with cavities is one explanation for negative cultures. These cases are best identified and managed by follow-up clinical and radiographic evaluation after 2–3 months of therapy to determine if there has been a response to antituberculosis treatment.

If patients exhibit either a clinical response or significant improvement in their chest radiograph after 2–3 months of treatment and no other etiology is identified, treatment should be continued for a total of 4–6 months for active tuberculosis.

## Case Three

A 60-year-old woman, who immigrated from China 1 month ago, is evaluated for tuberculosis. She denies symptoms of tuberculosis and has no history of previous tuberculosis or other significant past medical history. Her tuberculin skin test has 13 mm of induration. Her chest radiograph is shown in *Figure 3.4*.

**Figure 3.4**



1. How would you describe the chest radiograph in *Figure 3.4*?

Treatment was begun with isoniazid, rifampin, ethambutol, and pyrazinamide. Acid-fast smears and mycobacterial cultures of sputum were negative. After 8 weeks, she continued to be asymptomatic and her chest radiograph was without change.

2. What would be the **most** appropriate next step?

- A. Continue isoniazid, rifampin, and ethambutol to complete a 6-month course
- B. Stop ethambutol and pyrazinamide and continue isoniazid and rifampin for an additional 2 months
- C. Stop rifampin and isoniazid and continue ethambutol and pyrazinamide for an additional 4 months
- D. Add levofloxacin and ethionamide to his current antituberculosis medications

## ***Case Three Answers***

---

1. Right upper lobe fibronodular opacities with volume loss and hilar retraction. Right apical pleural thickening.

## ***Case Three Summary***

---

Patients with a positive tuberculin skin test who have radiographic evidence of prior tuberculosis and who have not received prior treatment are at increased risk for the subsequent development of tuberculosis.

The radiographic findings that constitute evidence of prior tuberculosis are upper lobe opacities, often with volume loss. Patients with radiographic findings of healed primary tuberculosis (e.g., calcified solitary pulmonary nodules, calcified hilar lymph nodes, and pleural thickening) are not at increased risk for tuberculosis compared with persons with normal chest radiographs.

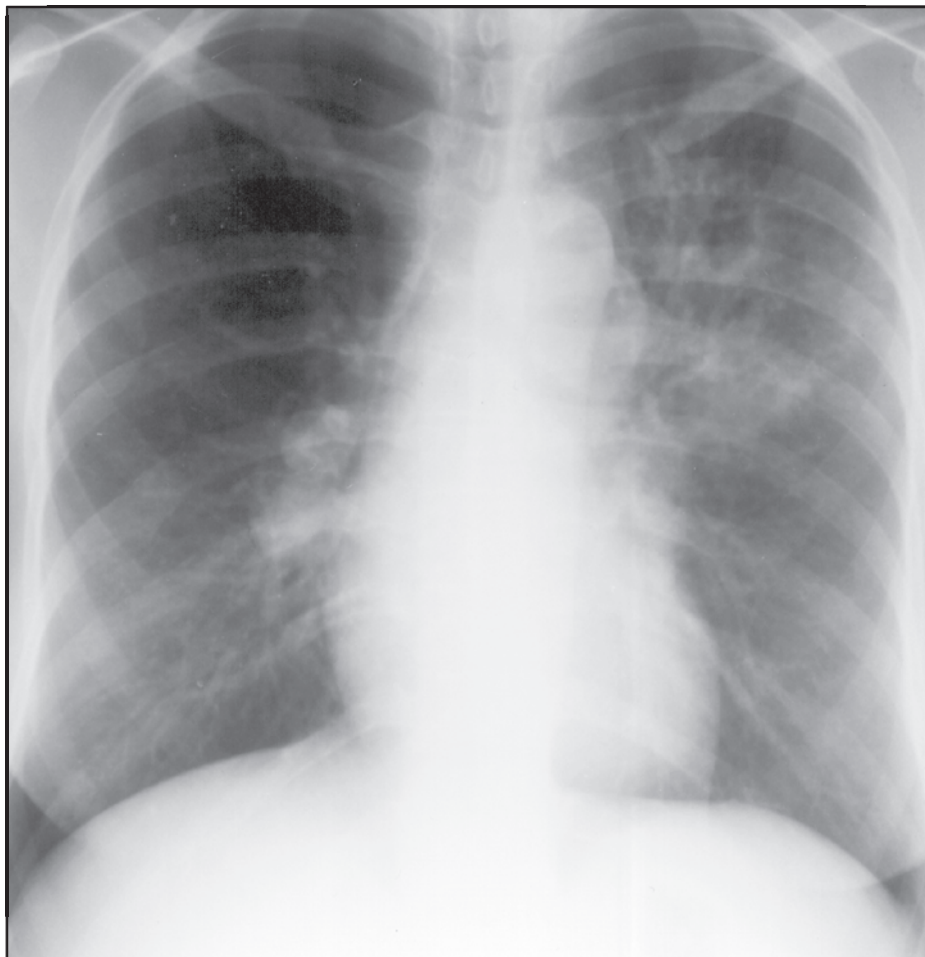
Disease activity cannot be determined from a single chest radiograph. Unless previous radiographs show that the abnormality has not changed, sputum examination should be performed to assess the possibility of active tuberculosis. Once active tuberculosis has been excluded, current recommendations for treatment of latent tuberculosis infection in persons with radiographic evidence of prior tuberculosis include isoniazid alone for 9 months or 4 months of rifampin (preferably with isoniazid).

The decision to initiate multidrug antituberculosis treatment at the initial evaluation should be based on the degree of clinical suspicion for active tuberculosis. If suspicion for active tuberculosis is high, multidrug therapy should be initiated before smear/culture results are known. If suspicion is low, treatment can be deferred until later when additional data have been obtained to clarify the diagnosis.

## Case Four

A 32-year-old male patient with AIDS presents with a history of fever, cough, dyspnea, and night sweats for the past 3 weeks. His last CD4 lymphocyte count was 200 cells/ $\mu$ L. His radiograph is shown in *Figure 3.5*.

**Figure 3.5**



1. How would you describe the chest radiograph in *Figure 3.5*?
2. Based on the clinical presentation and your reading of the chest radiograph, what would be the **least** likely diagnosis?
  - A. Tuberculosis
  - B. Fungal infection
  - C. *Pneumocystis carinii* pneumonia
  - D. *Mycobacterium kansasii* disease

## ***Case Four Answers***

---

1. Left upper lobe consolidation with areas of cavitation and mediastinal and hilar lymphadenopathy. Note the lymphadenopathy in the aortopulmonary window.

## ***Case Four Summary***

---

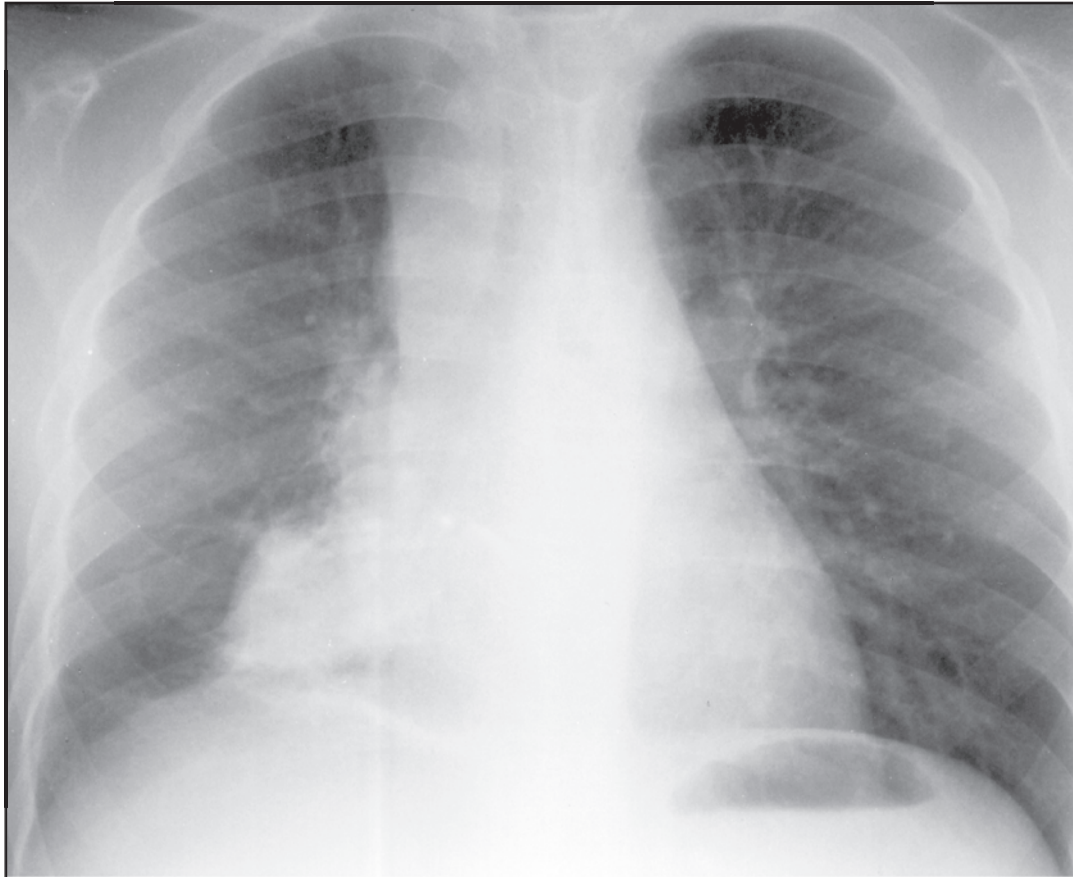
The patient had three acid-fast smears which were positive and the cultures grew *M. tuberculosis*. He was started on directly observed therapy with four antituberculosis medications.

HIV-infected patients who develop pulmonary disease often present challenging diagnostic dilemmas to clinicians. One reason is the myriad radiographic appearances the same infection can take in an HIV-infected individual. For example, tuberculosis in an HIV-infected person can appear as lower lung zone involvement, lymphadenopathy, and pleural effusion instead of the more typical post-primary reactivation pattern of upper lobe cavitory disease. As a general rule, the more immunosuppressed the patient, the more atypical the chest radiograph findings with respect to tuberculosis. Proper interpretation of the chest radiograph is critical in such patients to help guide the diagnostic evaluation. The presence of cavitation and lymphadenopathy in this patient made tuberculosis and other mycobacterial and fungal infections much more likely than *P. carinii* pneumonia.

## Case Five

The patient is a 4-year-old child who presents to a local hospital with a cough and wheezing. The child has no underlying medical conditions. He has recently been exposed to several cases of tuberculosis in his family. His chest radiograph is shown in *Figure 3.6*.

**Figure 3.6**



1. How would you describe the chest radiograph in *Figure 3.6*?
2. What would be the **most** appropriate next step?
  - A. Perform bronchoscopy to obtain a good respiratory specimen
  - B. Collect three sputum specimens for acid-fast smears and cultures
  - C. Begin a broad-spectrum antibiotic for community-acquired pneumonia
  - D. Begin multidrug antituberculosis therapy



### ***Case Five Answer***

---

1. Right paratracheal and hilar adenopathy and right lower lung zone consolidation with probable volume loss.

### ***Case Five Summary***

---

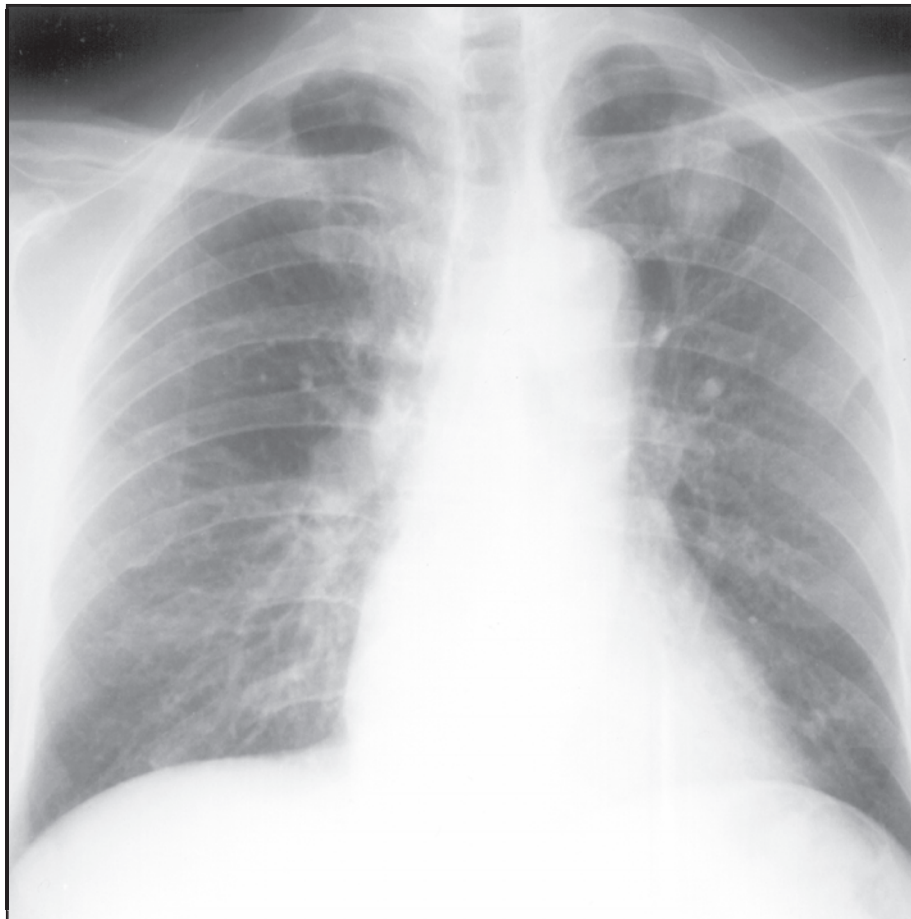It is often challenging to establish a diagnosis of tuberculosis in children because of difficulties in obtaining sputum or other diagnostic specimens. Symptom review and chest radiographs of children who have recently been in contact with adults with active tuberculosis should be carefully evaluated to detect evidence of active disease.

Findings suggestive of active tuberculosis include lymphadenopathy. Children in whom active tuberculosis is suspected on the basis of either symptoms or radiographs should have treatment with anti-tuberculosis therapy started. The best way to establish a diagnosis of pulmonary tuberculosis in children is from clinical and radiographic evidence and identification of a source case. Microbiological confirmation is frequently not available but is most likely to come from cultures of gastric aspirates. Cultures of gastric secretions are positive for *M. tuberculosis* in up to 40% of cases of pulmonary tuberculosis in children. When susceptibility results from the source case are imminent, gastric aspirates do not always need to be collected from the child.

## Case Six

A 71-year-old man is evaluated because of a 1-month history of a cough with occasional blood-streaked sputum. He denies fever or weight loss. He used to smoke cigarettes but stopped 23 years previously. He thought he was treated for tuberculosis in the past, but he is unable to provide any details of the therapy. The man arrived in the United States from the Philippines 8 months ago. The physical exam is unremarkable. A tuberculin skin test shows 11 mm in induration. No prior radiographs are available. Three sputum smears are negative for acid-fast bacilli. His chest radiograph is shown in *Figure 3.7*.

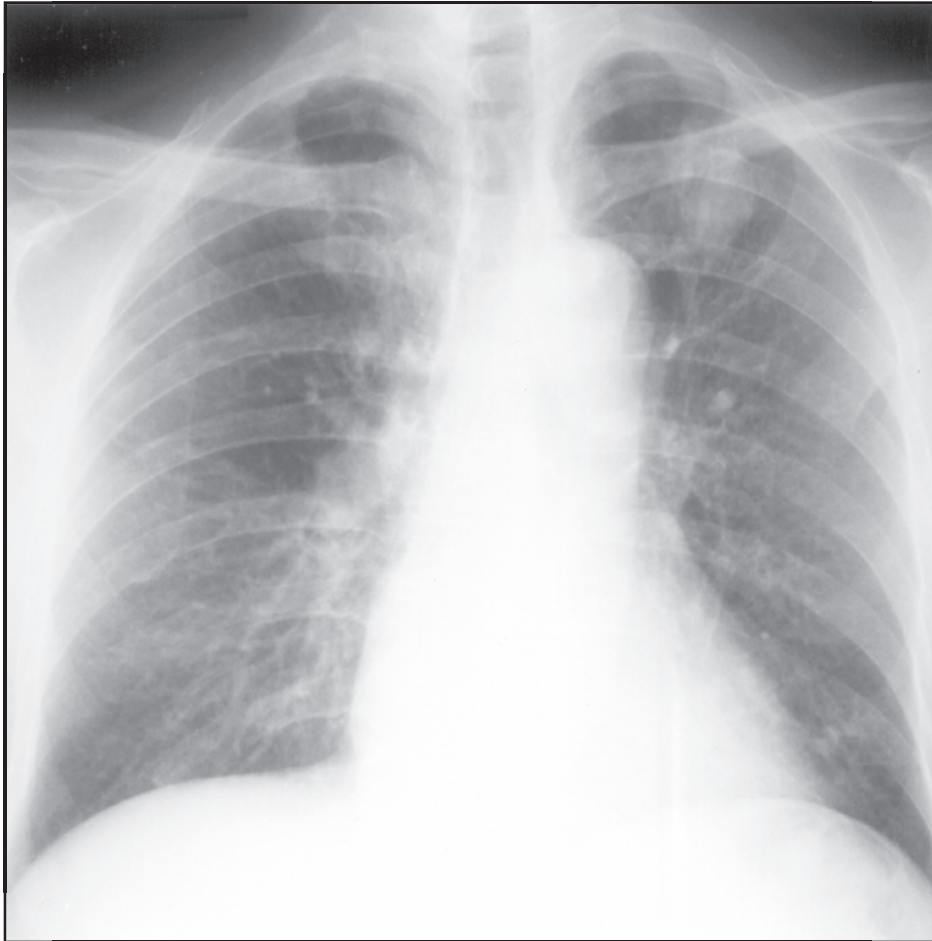
**Figure 3.7**



1. How would you describe this chest radiograph?
2. Which of the following would you do next?
  - A. Begin isoniazid for treatment of latent tuberculosis infection
  - B. Perform direct amplification test of sputum for *M. tuberculosis* complex
  - C. Repeat chest radiograph in six months
  - D. Begin multidrug therapy for tuberculosis

The patient was begun on multidrug therapy for tuberculosis. All sputum cultures were negative for mycobacteria and the patient still had intermittent hemoptysis. A repeat chest radiograph was taken 3 months after therapy started and is shown in *Figure 3.8*.

***Figure 3.8 - After 3 Months***



**3.** How would you describe the second chest radiograph in *Figure 3.8*?

4. What is the **most** appropriate next action?

- A.* Continue isoniazid, rifampin, ethambutol, and pyrazinamide for an additional 3 months
- B.* Continue isoniazid and rifampin for an additional 3 months
- C.* Obtain a CT of the chest
- D.* Stop all medications and schedule for repeat chest radiograph in 3 months

### ***Case Six Answers***

---

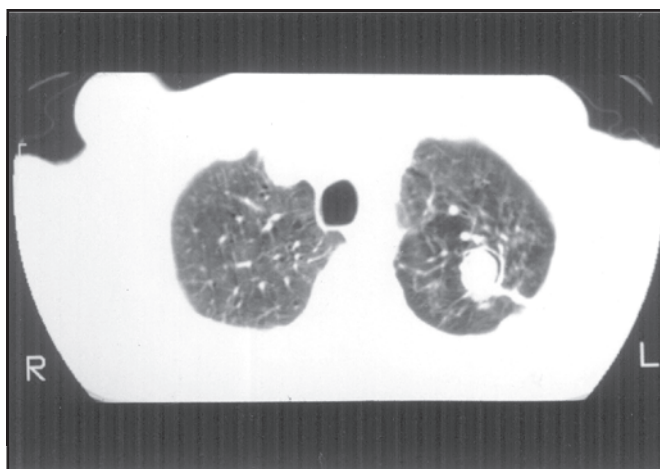
1. Left upper lobe focal rounded mass with crescent-shaped air collection in its superior aspect.
2. Left upper lobe focal rounded mass with crescent-shaped air collection in its superior aspect.
3. Left upper lobe focal rounded mass with crescent-shaped air collection in its superior aspect. There has been no significant change from the prior radiographs.

### ***Case Six Summary***

---

The first step in approaching a patient with a positive tuberculin skin test and an abnormal chest radiograph is to obtain sputum for acid-fast smears and cultures. Treatment should be given if clinical suspicion for active tuberculosis is high. If cultures do not yield tuberculosis and the patient does not exhibit a clinical or radiographic response to treatment, then the chest radiographic abnormality does not represent active tuberculosis, and another diagnosis should be pursued.

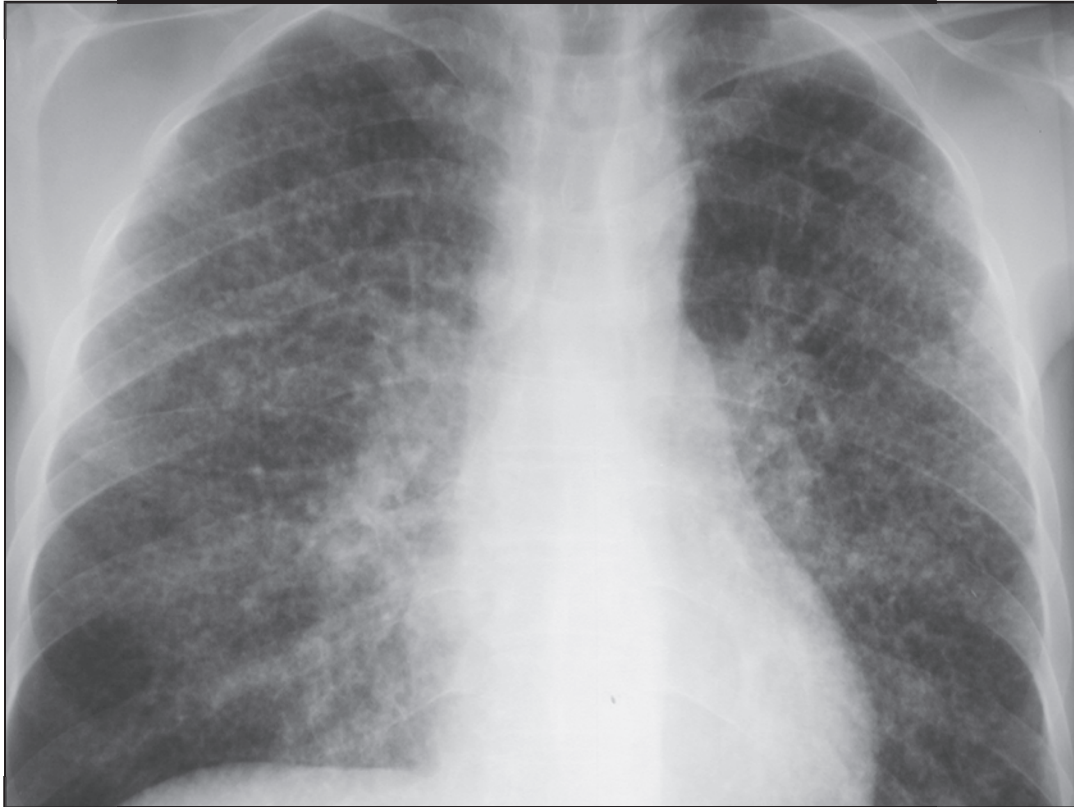The CT scan (shown below) indicates that the radiographic abnormality is a mycetoma, which is a fungus ball that develops in a preexisting cavity (in this case, as a result of prior tuberculosis). When a patient with a mycetoma develops massive hemoptysis, lung resection is the procedure of choice for definitive treatment.



## Case Seven

The patient is a 62-year-old man from India with a 3-month history of fevers, night sweats, intermittent cough, and a 10-kilogram weight loss. His chest radiograph is shown in *Figure 3.9*.

**Figure 3.9**



1. Describe the radiograph in *Figure 3.9* using standard terminology.
2. Which of the following diagnostic tests has the highest sensitivity for identifying *M. tuberculosis* in this patient?
  - A. Mycobacterial cultures of blood
  - B. Mycobacterial cultures of sputum
  - C. Mycobacterial cultures of transbronchial biopsies
  - D. Mycobacterial cultures of bronchoalveolar lavage fluid



## ***Case Seven Answers***

---

1. The radiograph in *Figure 3.9* shows multiple well-defined, small nodules, mostly 2–3 mm in diameter, that are widespread in distribution.

## ***Case Seven Summary***

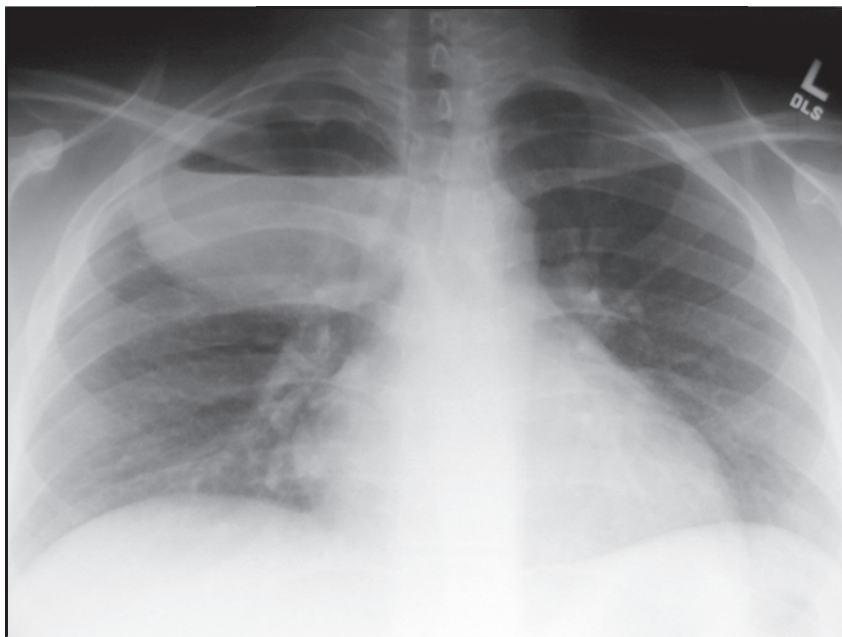
---

Miliary tuberculosis is a classic radiographic manifestation of disseminated tuberculosis and consists of the presence of small nodules on the chest radiograph. Miliary nodules are defined by multiple, small discrete opacities, mostly 2 mm in diameter, that are widespread in distribution. The miliary pattern results from hematogenous dissemination of tubercle bacilli, which explains its widespread distribution. It is not specific for tuberculosis and can also be seen in disseminated fungal infections and some malignancies (e.g., renal cell carcinoma). Because the miliary pattern is an example of an interstitial pattern, transbronchial tissue provides the highest diagnostic yield. Transbronchial tissue should be examined for the presence of granulomas and cultured for mycobacteria (yield: 50–70%). Because miliary tuberculosis almost always involves other organs, diagnostic alternatives include biopsies of bone marrow (especially in patients with cytopenias) and liver (especially in patients with elevated serum alkaline phosphatase), and cultures of urine. Given the high mortality of disseminated tuberculosis, evaluation should occur without delay.

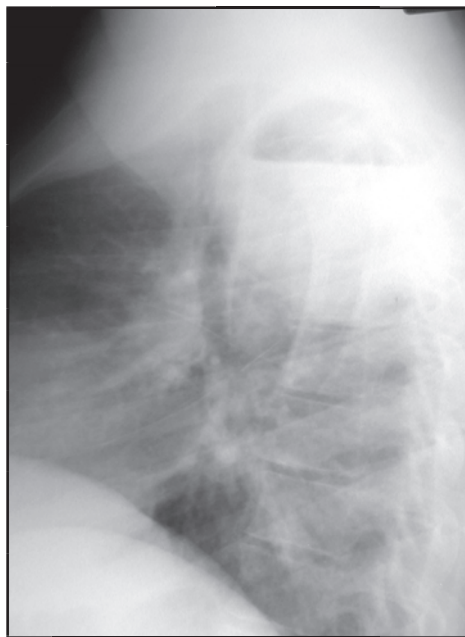
## Case Eight

The patient is a 54-year-old woman with a 5-week history of a cough productive of foul-smelling sputum, fever and night sweats. Medical problems include a history of chronic obstructive pulmonary disease and heavy alcohol use. Her last tuberculin skin test 3 years ago had 13 mm of induration. Her chest radiographs are shown in *Figures 3.10a* and *3.10b*.

**Figure 3.10a, Frontal**



**Figure 3.10b, Lateral**



1. Describe the radiographs *Figures 3.10a* and *3.10b* using standard terminology.
2. Which of the following would be the **most** appropriate treatment for this patient?
  - A. Doxycycline
  - B. Clindamycin
  - C. Isoniazid, rifampin, pyrazinamide, and ethambutol
  - D. Fluconazole

**Case Eight Answer**

---

1. The radiographs in *Figures 3.10a* and *3.10b* show a large air-filled spherical density in the right upper lobe that has an air-fluid level.

**Case Eight Summary**

---

It is important to identify and properly characterize focal lucent areas on the chest radiograph. There are many causes of focal lucent lesions on chest radiographs, but diseases that result in cavitation are among the most important. Causes of pulmonary cavitation include tuberculosis, lung abscess, pulmonary infarction, bronchogenic cancer, and non-infectious inflammatory diseases (e.g., Wegener's granulomatosis). These diseases have different clinical presentations, so obtaining a good history is an important first step. The next step in the diagnostic evaluation is usually collecting sputum for microbiologic studies and cytologic examination. Patients should also be placed in respiratory isolation if tuberculosis is suspected on the basis of either the radiographic findings or clinical examination.

## ***Conclusion***

These cases demonstrate important principles regarding the interpretation of chest radiographs and the diagnosis and treatment of tuberculosis. One such principle is that it is essentially impossible to distinguish active from inactive tuberculosis from a single chest radiograph. Therefore, sputum should be obtained in any patient with an abnormal chest radiograph in whom a diagnosis of tuberculosis is being considered.

The radiographic findings that constitute evidence of prior tuberculosis are upper lobe opacities, often with volume loss. Persons with radiographic findings of healed primary tuberculosis (e.g., calcified solitary pulmonary nodules, calcified hilar lymph nodes, and pleural thickening) are not at increased risk for tuberculosis compared with persons having normal chest radiographs.

Another basic principle is that if clinical suspicion is high that a patient has active tuberculosis, treatment should be administered immediately rather than waiting for culture confirmation, which can take up to 8 weeks. If cultures cannot be obtained or are negative for tuberculosis, a follow-up clinical and radiographic evaluation can be extremely helpful in determining whether active disease is present. If there is either a clinical response to antituberculosis treatment or significant improvement in the chest radiograph after 2–3 months of treatment, and no other etiology is identified, treatment should be continued for active tuberculosis.

Once active tuberculosis has been excluded (i.e., no clinical or radiographic response to treatment and negative cultures), current recommendations for treatment of latent tuberculosis infection in patients with radiographic evidence of prior tuberculosis include isoniazid alone for 9 months or 4 months of rifampin (preferably with isoniazid).

Proper interpretation of the chest radiograph is an essential component of the diagnostic evaluation. For example, the radiographic finding of miliary nodules signifies disseminated tuberculosis because it results from hematogenous spread of tubercle bacilli. Because the miliary pattern is an example of an interstitial pattern, bronchial tissue (best obtained by transbronchial biopsies) provides the highest diagnostic yield and should be both examined for the presence of caseating granulomas and cultured for acid-fast organisms.

Children and HIV-infected persons with tuberculosis often present challenging diagnostic and treatment dilemmas for clinicians. It is often quite difficult to establish a definitive microbiological diagnosis in children, so clinical suspicion is usually the reason treatment is started. Clinical suspicion for tuberculosis in children is often based on a positive tuberculin skin test and an abnormal chest radiograph showing lymphadenopathy.

The treatment of HIV-infected patients with tuberculosis can be complicated by 1) drug interactions between rifamycins, such as rifampin or rifabutin, and antiretroviral therapy such as protease inhibitors and nonnucleoside reverse transcriptase inhibitors; and 2) paradoxical reactions as a result of immune reconstitution, particularly if they are taking antiretroviral therapy. Clinicians should seek the advice of experts in the care of HIV-infected persons with tuberculosis if these issues arise.

## References

American Thoracic Society. Rapid diagnostic tests for tuberculosis: what is the appropriate use? *Am J Respir Crit Care Med*. 1997;155:1804-1814.

American Thoracic Society and Centers for Disease Control and Prevention. Targeted tuberculin testing and treatment of latent tuberculosis infection. *Am J Respir Crit Care Med*. 2000;161:S221-S247.

Binkin NJ, Zuber PL, Wells CD, Tipple MA, Castro KG. Overseas screening for tuberculosis in immigrants and refugees to the United States: current status. *Clin Infect Dis*. 1996;23:1226-1232.

Foulds J, O'Brien R. New tools for the diagnosis of tuberculosis: the perspective of developing countries. *Int J Tuberc Lung Dis*. 1998;2:778-783.

Harries AD, Maher D, Nunn P. An approach to the problems of diagnosing and treating adult smear-negative pulmonary tuberculosis in high-HIV-prevalence settings in sub-Saharan Africa. *Bull World Health Organ*. 1998;76:651-662.

Havlir DV, Barnes PF. Tuberculosis in patients with human immunodeficiency virus infection. *N Engl J Med*. 1999;340:367-373.

Hopewell PC. A clinical view of tuberculosis. *Radiol Clin North Am*. 1995;33:641-653.

Jamieson FB, Chedore P. Tuberculosis in the 1990s: from bedside to bench and back. *Can Respir J*. 1999;6:341-344.

Kahn EA, Starke JR. Diagnosis of tuberculosis in children: increased need for better methods. *Emerg Infect Dis*. 1995;1:115-123.

Kennedy DJ, Lewis WP, Barnes PF. Yield of bronchoscopy for the diagnosis of tuberculosis in patients with human immunodeficiency virus infection. *Chest*. 1992;102:1040-1044.

McAdams HP, Erasmus J, Winter JA. Radiologic manifestations of pulmonary tuberculosis. *Radiol Clin North Am*. 1995;33:655-678.

## ***Glossary***

<b>Absorption</b>	As applied to radiography, the act of attenuating an x-ray beam. Tissues of different densities have differing numbers of x-ray photons and therefore appear relatively “black” (less dense) or “white” (denser) on an x-ray film.
<b>Acinar shadow</b>	A round or ovoid, poorly defined pulmonary opacity 4-8 mm in diameter, presumed to represent a pulmonary acinus rendered opaque by consolidation. This term is usually used in the presence of many such opacities.
<b>Air bronchogram</b>	The radiographic shadow of an air-filled bronchus peripheral to the hilum and surrounded by airless lung (whether by virtue of absorption of air or replacement of air or both). The air is visible within the bronchus because the lung surrounding the bronchus is airless. Visualization of an air bronchogram usually implies the presence of an airspace filling process
<b>Aortopulmonary window</b>	Mediastinal space surrounded anteriorly by the ascending aorta; posteriorly by the descending aorta; superiorly by the aortic arch; inferiorly by the left pulmonary artery; laterally by the left lung; and medially by the left aspect of the trachea, left mainstem bronchus, and esophagus. This space normally contains the ductus ligament, the left recurrent laryngeal nerve, lymph nodes, and fat.
<b>Atelectasis</b>	Less-than-normal inflation of all or part of a lung with corresponding diminution in volume, often resulting in loss of the normal lucency of the affected portion of lung.
<b>Attenuation</b>	A collective term for the processes (absorption and scattering) by which the energy of an x-ray beam is diminished in its passage through matter.
<b>Bronchopleural fistula</b>	An abnormal connection between the pulmonary parenchyma and the pleural space. Because bronchi conduct air to the alveoli in the pulmonary parenchyma, such a connection functionally represents direct communication between a bronchus and the pleural space. A bronchopleural fistula is usually manifest on a radiograph as a persistent, often large, pneumothorax, frequently with an air leak when a thoracostomy tube is in place.
<b>Cavitation</b>	The process by which a cavity is formed.
<b>Cavity</b>	A gas-filled space within a zone of pulmonary consolidation or within a mass or nodule, produced by expulsion of the necrotic part of the lesion via the bronchial tree. Cavities may or may not contain a fluid level or internal opacity and are characterized with regard to wall thickness and character.
<b>Consolidation</b>	The process by which air in the lung is replaced by the products of disease rendering the lung solid (as in the case of pneumonia). Radiographically, consolidation is seen as relatively homogeneous opacity in the lung with little or no volume loss, effacement of pulmonary blood vessels, and sometimes the presence of the air bronchogram.
<b>Cyst</b>	A circumscribed space in the lung, 1 cm or more in diameter, containing gas or liquid, whose wall is generally thin, well defined, and composed of a variety of cellular elements.
<b>Density</b>	The opacity of a radiographic shadow to visible light. A qualitative expression of the degree of film blackening, usually expressed in terms of the blackening of one film or shadow with respect to another.



## Glossary

<b>Differential x-ray absorption</b>	The process by which different numbers of x-ray photons are attenuated by matter, due to differences in the densities of the various components of the matter. When the attenuating matter is human tissue, the process of differential x-ray absorption is responsible for the creation of the radiographic image.
<b>Endobronchial spread</b>	Spread of infected material through the bronchial tree. Radiographically, endobronchial spread often appears as a collection of ill-defined nodules, commonly 4–8 mm in diameter, and often distributed in a segmental or lobar fashion. The nidus of infection, such as a cavity, may be evident. This pattern of disease spread is typical of bacterial causes of infection, including tuberculosis.
<b>Ground glass</b>	Any extended, finely granular pattern of pulmonary opacity within which normal anatomic details are partially (not completely) obscured. Compare with <i>consolidation</i> , in which the underlying anatomic details are completely obscured.
<b>Hematogenous dissemination</b>	Widely but discontinuously distributed throughout an organ or type of tissue. The pattern of hematogenous dissemination is the result of pathology delivered to an organ via the circulation. In the lung the pattern is usually one of well-defined nodules of various sizes distributed throughout the lung, perhaps with a slight basal predominance due to the relatively greater blood flow present in the bases.
<b>Honeycomb pattern</b>	A number of closely approximated ring shadows representing coalesced airspaces, usually lined with bronchiolar epithelium, 5–10 mm in diameter with walls 2–3 mm thick composed of dense fibrous tissue. This finding implies “end-stage” lung fibrosis.
<b>Hydropneumothorax</b>	The presence of both gas and fluid in the pleural cavity.
<b>Interface</b>	The boundary between the shadows of two juxtaposed structures or tissues of different texture or opacity.
<b>Interstitium</b>	A continuum of loose connective tissue throughout the lung comprising three subdivisions: the bronchovascular interstitium (surrounding the pulmonary arteries, veins, and bronchi), the parenchymal interstitium (between the alveolar and capillary basement membranes), and the sub-pleural interstitium (beneath the visceral pleural and within interlobular septa).
<b>Kerley’s line (septal line)</b>	A linear opacity which, depending on its location, extent, and orientation, may be further classified as follows:
- Kerley’s A line	An essentially straight linear opacity 2–6 cm long and 1–3 mm wide, usually situated in an upper lung zone, that points to the hilum centrally and is directed toward but does not extend to the pleural surface.
- Kerley’s B line	An essentially straight linear opacity 1.5–2 cm long and 1–2 mm wide, usually situated in the lung base and oriented at right angles to the pleural surface with which it is usually in contact peripherally.
- Kerley’s C line	A group of branching, linear opacities producing the appearance of a fine net, situated at the lung base and representing Kerley’s B lines seen <i>en face</i> .

## Glossary

<b>Linear opacity</b>	A shadow resembling a line; an elongated opacity of uniform width, qualified with regard to length, width, orientation, and anatomic location.
<b>Lucency</b>	The ability to transmit light, and thus the ability to transmit x-radiation.
<b>Lymphadenopathy</b>	Any abnormality of lymph nodes, usually restricted to enlargement.
<b>Mass</b>	A pulmonary or pleural lesion represented in a radiograph by a discrete opacity 30 mm or greater in diameter, explicitly shown or presumed to be extended in all three dimensions. Should be qualified with regard to opacity (especially presence of calcification), homogeneity, border characteristics, location, and number.
<b>Miliary pattern</b>	A collection of tiny discrete pulmonary opacities that are generally uniform in size and widespread in distribution, each of which measures 2 mm or less in diameter. This pattern usually implies a bloodborne source (see <i>hematogenous dissemination</i> ).
<b>Nodular pattern</b>	A collection of innumerable small, roughly circular, discrete pulmonary opacities ranging in size from 2–10 mm, generally uniform in size and widespread in distribution.
<b>Nodule</b>	Any pulmonary or pleural lesion represented in a radiograph by a discrete opacity 2-30 mm diameter, explicitly shown or presumed to be extended in all three dimensions. Should be qualified with regard to opacity (especially presence of calcification), homogeneity, border characteristics, location, and number.
<b>Opacity</b>	The capacity to attenuate an x-ray beam; the degree of attenuation of the x-ray beam, usually expressed in terms of the attenuation of one absorber to another. In a radiograph, an opacity is a circumscribed area that appears nearly white (i.e., denser) than its surroundings. Use of the term opacity does not imply location; opacity may be parenchymal, pleural, within the chest wall, or external to the patient.
<b>Parenchyma</b>	The gas-exchanging portion of the lung, consisting of alveoli and their capillaries, estimated to constitute approximately 90% of total lung volume. On a radiograph, pulmonary parenchyma appears as lung exclusive of visible pulmonary vessels and airways.
<b>Photon</b>	In physics, a corpuscle of energy or particle, a quantum of light energy.
<b>Pleural effusion</b>	The presence of fluid within the pleural space.
<b>Pleural thickening</b>	An increase in thickness of the pleura, usually resulting from prior inflammation with subsequent fibrosis or tumor. The presence of pleural thickening may be suggested when pleural opacity is stable for long periods of time on serial radiographs (usually over a period of months or years) or when the pleural opacity fails to demonstrate mobility on decubitus radiographs. Note that in the latter circumstance, loculated pleural fluid collections may behave similarly, and thus the lack of mobility of a pleural opacity with decubitus radiographs is not pathognomonic for pleural thickening.
<b>Post-primary tuberculosis (reactivation TB)</b>	The development of tuberculosis one or more years after initial infection, usually appearing as nodular and linear areas of increased opacity in the upper lobes, often with cavitation.
<b>Primary tuberculosis</b>	Direct progression of the initial infection with <i>M. tuberculosis</i> , usually appearing as consolidation in the lower lobes, often accompanied by hilar and mediastinal lymphadenopathy and pleural effusion.

## Glossary

<b>Reticular pattern (reticulation)</b>	A collection of innumerable small linear opacities that together produce the appearance of a net.
<b>Reticulonodular pattern</b>	A collection of innumerable small linear and small nodular opacities that together produce a composite appearance resembling a net with small superimposed nodules. The linear and nodular elements are usually similar in magnitude.
<b>Retrosternal clear space</b>	The lung parenchyma visible on the lateral radiograph posterior to the sternum. Usually only a few pulmonary blood vessels are visible in this region.
<b>Right paratracheal stripe</b>	A vertically oriented linear opacity 2–3 mm wide that extends from the thoracic inlet to the right tracheobronchial angle on the frontal radiograph. It is situated between the air shadow of the trachea and the right lung and is formed by the right wall of the trachea and contiguous mediastinal tissue and adjacent pleura.
<b>Scatter</b>	Pertaining to radiography, <i>scatter</i> refers to radiation that enters a patient and is deflected from its initial course but that may still contact and expose the x-ray film. Scatter radiation contributes to the patient radiation dose and degrades the radiographic image.
<b>Septal line</b>	A generic term for fine linear opacities of varied distribution produced by the interstitium between pulmonary lobules when the interstitium is thickened by fluid, dust deposition, cellular material, etc. See also <i>Kerley's lines</i> .
<b>Silhouette sign</b>	The effacement of an anatomic soft tissue border by consolidation of the adjacent lung or accumulation of fluid in the contiguous pleural space. This is a sign of conformity, and, hence, of the probable adjacency of a pathologic opacity to a known structure. The silhouette sign is useful for detecting and localizing consolidation along the axis of the x-ray beam.
<b>Stripe</b>	An extended, longitudinal, composite opacity 2–5 mm wide, used as a descriptor of shadows created by mediastinal structures.
<b>Unabsorbed</b>	Pertaining to radiography, the term <i>unabsorbed</i> refers to that portion of the x-ray beam that traverses the patient and does not interact with the patient's tissues. These x-ray photons pass through the patient unaffected and expose the x-ray film, thereby contributing to the creation of the radiographic image.

## Glossary References

Tuddenham WJ, and the Nomenclature Committee of the Fleischner Society. Glossary of terms for thoracic radiology: recommendations of the Nomenclature Committee of the Fleischner Society. *Am J Roentgenol*. 1984;143:509-517.